

1 ***AN INTERNATIONAL CONTINENCE SOCIETY (ICS)***

2 ***REPORT ON THE TERMINOLOGY***

3 ***FOR PELVIC FLOOR MUSCLE ASSESSMENT***

4
5 ***Helena Frawley[^], Beth Shelly*[^], Melanie Morin[^],***

6 ***Stéphanie Bernard[^], Kari Bø[^]; Giuseppe Alessandro Digesu*[^], Tamara Dickinson,***

7 ***Sanchia Goonewardene; Doreen McClurg[^], Mohammad Sajjad Rahnama'i[^], Alexis Schizas,***

8 ***Marijke Slieker-ten Hove, Satoru Takahashi, Jenniffer Voelkl Guevara[^]***

9 ***Standardization Steering Committees ICS*, ICS Working Group on***

10 ***Terminology for Pelvic Floor Muscle Assessment.[^]***

11
12 *Helena Frawley: The University of Melbourne. Australia. h.frawley@unimelb.edu.au*

13 *Beth Shelly: Moline. Illinois. U.S.A. beth@bethshelly.com*

14 *Melanie Morin: University of Sherbrooke. Québec. Canada. Melanie.M.Morin@usherbrooke.ca*

15 *Stéphanie Bernard: Université Laval. Québec. Canada. stephanie.bernard@cirris.ulaval.ca*

16 *Kari Bø: Norwegian School of Sports Sciences, Dept of Sports Med, Oslo/Akershus university*

17 *hospital, Dept of Obstet Gynecol, Lørenskog, Norway. kari.bo@nih.no*

18 *Tamara Dickinson: UT Southwestern Medical Center, Dallas. U.S.A.*

19 *Tamara.Dickinson@UTSouthwestern.edu*

20 *Giuseppe Alessandro Digesu: St Mary's Hospital, Imperial College, London. United Kingdom.*

21 *a.digesu@imperial.ac.uk*

22 *Sanchia Goonewardene: Royal Free/ UCL Hospitals. London. United Kingdom.*

23 *ssg7727@yahoo.co.uk*

24 *Doreen McClurg: Glasgow Caledonian University. United Kingdom. Doreen.McClurg@gcu.ac.uk*

25 *Mohammad Sajjad Rahnama'i: University Hospital of Aachen, Germany and Maastricht University*
26 *Medical Centre. The Netherlands. Sajjad_r@yahoo.com*
27 *Alexis Schizas United Kingdom. ampschizas@gmail.com*
28 *Marijke Slieker-ten Hove: University of Erasmus. Rotterdam. ProFundum Instituut, The*
29 *Netherlands. mcpslieker@gmail.com*
30 *Satoru Takahashi: Nihon University. Tokyo. Japan. takahashi.satoru@nihon-u.ac.jp*
31 *Jenniffer Voelkl Guevara: University Hospital Fundación Sante Fé de Bogotá. Colombia.*
32 *jvoelkl28@gmail.com*

33

34 Correspondence to:

35 Associate Professor Helena Frawley,

36 The University of Melbourne, Melbourne. Victoria. Australia.

37 Tel: +61 418584813; h.frawley@unimelb.edu.au

38

39

40 **ABSTRACT**

41 **Introduction:** The terminology for female and male pelvic floor muscle (PFM) assessment has
42 expanded considerably since the first PFM function and dysfunction standardisation of
43 terminology document in 2005. New terms have entered assessment reports, and new
44 investigations to measure PFM function and dysfunction have been developed. An update of
45 this terminology was required to comprehensively document the terms and their definitions,
46 and to describe the assessment method and interpretation of the finding, in order to standardise
47 assessment procedures and aid diagnostic decision-making.

48 **Methods:** This report combines the input of members of the Standardisation Committee of the
49 International Continence Society (ICS) Working Group 16, with contributions from recognized
50 experts in the field and external referees. A logical, sequential clinically-directed assessment
51 framework was created against which the assessment process was mapped. Within categories
52 and subclassifications, each term was assigned a numeric coding. A transparent process of 11
53 rounds of full working group and external review was undertaken to exhaustively examine each
54 definition, plus additional extensive internal development, with decision-making by collective
55 opinion (consensus).

56 **Results:** A Terminology Report for the symptoms, signs, investigations and diagnoses
57 associated with PFM function and dysfunction, encompassing 185 separate
58 definitions/descriptors, has been developed. It is clinically-based with the most common
59 assessment processes defined. Clarity and user-friendliness have been key aims to make it
60 interpretable by clinicians and researchers of different disciplines.

61 **Conclusion:** A consensus-based Terminology Report for assessment of PFM function and
62 dysfunction has been produced to aid clinical practice and be a stimulus for research.

63

64

65 **WORDS**

66 **(Abstract):** 248

67 **(Introduction-Section 4):** including tables and figures: 18,265

68 **(Footnotes):** 2,144

69 **(Appendix):** -

70

71 **TABLES** 27

72 **FIGURES** 12

73

74 **DISCLOSURES:**

75 **Helena Frawley:** Nil to disclose

76 **Beth Shelly:** Nil to disclose

77 **Melanie Morin:** Nil to disclose

78 **Stéphanie Bernard:** Nil to disclose

79 **Kari Bø:** Nil to disclose

80 **Tamara Dickinson:** Nil to disclose

81 **Giuseppe Alessandro Digesu:** Nil to disclose

82 **Sanchia Goonewardene:** Nil to disclose

83 **Doreen McClurg:** Nil to disclose

84 **M Sajjad Rahnama’i:** Consultant for Bioness, Dr Pflieger, Astellas and Janssen

85 **Alexis Schizas:** Nil to disclose

86 **Marijke Slieker-ten Hove:** KOL Indiba

87 **Satoru Takahashi:** Nil to disclose

88 **Jenniffer Voelkl Guevara:** Nil to disclose.

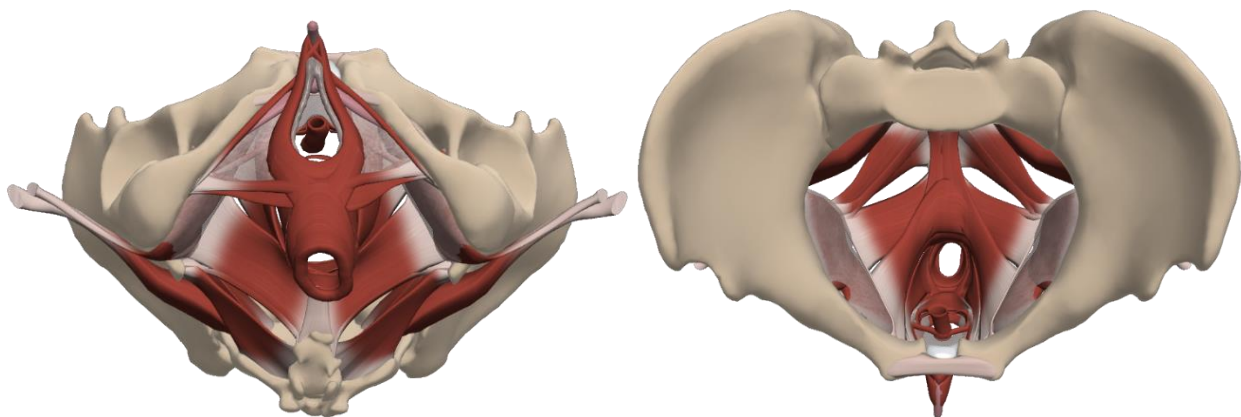
89

90

91 **INTRODUCTION:**

92 The current terminology used in the assessment and diagnosis of pelvic floor muscle (PFM) function
93 and dysfunction is both diverse and variably defined, with no current consensus which captures,
94 defines and describes all terms. This document lists and describes terms which are used in the neuro-
95 myo-fascial assessment and diagnosis of the PFM to aid teaching and standardisation of terminology
96 in this field. The terminology covers the assessment of both structure and function of the PFM. The
97 pelvic floor structures defined in this document include muscular tissues in the pelvic floor and their
98 neural connections, and the fascial (connective tissue) layers surrounding the PFM fibres/fascicles. In
99 this document, assessment of the PFM is presented according to the perineal and pelvic regions of
100 PFM. While PFM anatomy nomenclature varies according to texts, the following structures are
101 considered to be the muscles that make up the perineum and the pelvic floor/levator ani⁽¹⁾. The perineal
102 region is divided into the anterior and posterior triangles. The anterior urogenital triangle comprises
103 the superficial urogenital muscles (bulbospongiosus/bulbocavernosus, ischiocavernosus and the
104 superficial transverse perinei), and the deep urogenital muscles (external urethral sphincter and deep
105 transverse perinei). The posterior (anal) triangle comprises the external anal sphincter. The levator ani
106 is comprised of pubococcygeus (which includes puborectalis, pubovisceralis, pubovaginalis, etc),
107 iliococcygeus and ischiococcygeus/coccygeus (considered vestigial). The female and male perineal
108 and PFM, inferior and superior views, are illustrated in Figure 1.

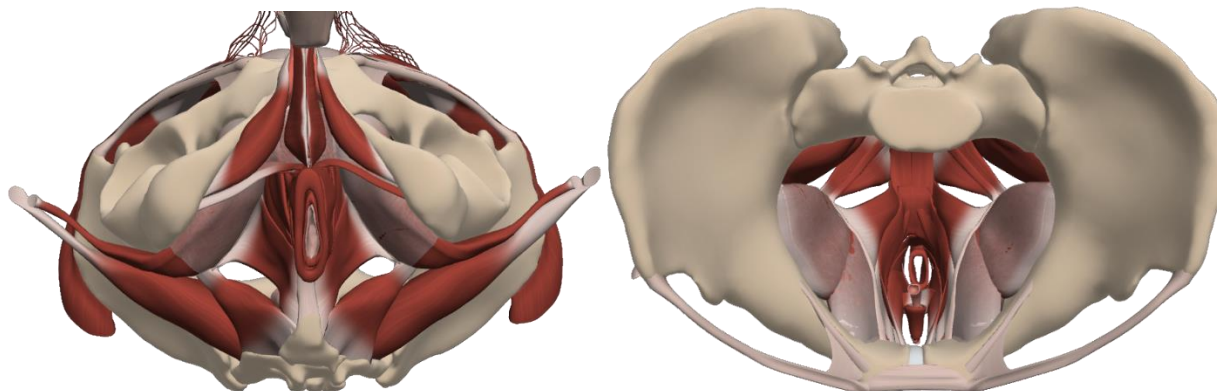
109



110

111 Figure 1a Muscles of the female perineum and pelvic floor, inferior and superior views (reprinted with
112 permission from Primal pictures⁽²⁾)

113



114

115 Figure 1b Muscles of the male perineum and pelvic floor, inferior and superior views (reprinted with
116 permission from Primal pictures⁽²⁾)

117

118 When referencing this document, the reader is asked to keep the term in context with PFM assessment.

119 The PFM terms included apply to adult females and males presenting with different types of pelvic
120 floor disorders. Assessment techniques are undertaken externally (*per perineum* (PP), and internally
121 (*per vaginam* (PV) or *per rectum* (PR)). Where the definition or description of the term requires
122 modification to differentiate between female (*f*) and male (*m*) assessment, this is indicated.

123

124 The search strategy used for this document was performed according to International Continence
125 Society (ICS) Standardisation Steering Committee guidelines. The working group of multi-national
126 and multi-disciplinary committee members applied expert opinion to identify existing terms that refer
127 to PFM assessment. Existing published ICS Standardization of Terminology documents were searched
128 and terms added to cover all published terms or in common clinical use that refer to the assessment of
129 PFM function and dysfunction. Inclusion of the final list of terms was achieved via a consensus
130 process, which took place between 2017 – 2019. The final list of terms serves as a reference for future

131 refinement and testing for clinical utility. This document is not a clinical protocol or guideline for how
132 to perform a PFM assessment, it defines and describes terms which may be used in a clinical
133 assessment of PFM function. As such, this document does not include within its scope other important
134 considerations when undertaking a PFM assessment. These include but are not limited to competency
135 of the assessor, clinical reasoning required for diagnostic decision-making, protocol when conducting
136 a sensitive examination of an intimate body part, appropriate informed consent, and ethical and legal
137 considerations⁽³⁾. Further, only a brief, introductory level description of how to undertake the test is
138 provided, not a detailed description of the exercise protocol using that tool, with the reader directed to
139 other texts for more detailed description.

140

141 If a term relevant to PFM assessment does not currently exist in an ICS Standardisation of Terminology
142 document, it is indicated as a “**NEW**” term. When a term appears in an existing ICS Standardisation
143 of Terminology document, the term definition and description is reproduced here with reference to the
144 original terminology document, in order to present a complete framework of PFM assessment. When
145 a modification to the existing term occurs, the word “**CHANGED**” is used. If the change is a
146 significant alteration from the existing term, a footnote is used to explain the reason for modification,
147 and a reference to the original term cited. Several of the terms related to ultrasound imaging have been
148 drawn from the AIUM/IUGA practice parameter for the performance of Urogynecological ultrasound
149 examinations document⁽⁴⁾. Similarly, terms in the algometry section already exist in the field of pain
150 science, and terms related to muscle function exist in the field of exercise physiology, etc. These terms
151 are labelled **NEW** for the purposes of this document however we acknowledge that these terms are
152 already published and may be in widespread use.

153

154 Table 1: Total, new and changed ICS definitions

Section	New Definitions / Descriptors	Changed Definitions / Descriptors	Unchanged Definitions / Descriptors	Total
Introduction & Symptoms	1	1	0	2
Signs	31	15	12	58
Investigations	80	18	17	115
Diagnoses	7	3	0	10
Total	119 (64%)	37 (20%)	29 (16%)	185

155

156 There is a plethora of existing terms and conceptual and operational definitions related to PFM function
157 and dysfunction⁽⁵⁾. Saltiel et al⁽⁵⁾ observed inconsistency and redundancy in PFM function terminology
158 and suggested that a further consideration of PFM function terms relevant to research and to clinical
159 practice is required⁽⁵⁾. A mapping of PFM function terms to the WHO International Classification of
160 Functioning, Disability and Health (ICF) framework has been recently proposed⁽⁶⁾, leading to a list of
161 the most frequently used terms⁽⁷⁾. In this paper, we define the assessment term, describe the application
162 of the test and interpretation of its finding within a framework of diagnostic decision-making and
163 clinical reasoning. This follows the usual order of assessment undertaken by a clinician or researcher
164 (referred to in this paper as an ‘assessor’), leading to a presumed diagnosis and formulation of a
165 treatment plan, to help guide clinical practice. This process includes the use of a patient's history,
166 patient-reported symptoms/outcomes, and information gained from clinical signs and the results of
167 investigations. It is important to recognize that neuro-musculo-skeletal structures beyond the PFM
168 muscles (e.g. intra- and extra pelvic muscles, the bony pelvis and pelvic girdle joints and central
169 nervous system factors) may impact on PFM function, however terminology relating to the assessment
170 of these structures and systems is beyond the scope of this paper.

171

172 We hope the terminology sited within this framework provides greater clarity and aids standardisation
173 of the usage of these terms. Where possible, the sequence of the terminology follows this order: the
174 region of assessment, the type of evaluation being undertaken, the name ('term') of the test /
175 assessment being undertaken, the definition of that term, the description of how that assessment
176 method is undertaken, how the assessment is rated and the terminology used to describe the finding.

177

178 **Limitations**

179 Normative data of PFM structure and function are lacking for the majority of PFM terms, which
180 hinders the ability to rate or interpret the finding as 'normal' or 'abnormal'. In addition, due to the lack
181 of known validity, reliability and responsiveness to change and diagnostic test accuracy (sensitivity,
182 specificity) of many of the commonly used PFM clinical assessment methods, investigations and
183 diagnoses, the clinical utility of these terms remains unknown. Therefore, this document is not intended
184 to be an evidence-based recommendation of which tests should be included in a PFM assessment;
185 rather our aim is to define and describe currently used terms, which subsequent research may
186 recommend for or against using in PFM assessment. Evidence to support or abandon the use of any of
187 these terms and assessment methods is eagerly awaited. In the meantime, we advise assessors to
188 exercise great caution in their interpretation of clinical findings, especially those measured with visual
189 observation, digital palpation and outputs of some of the available assessment tools, as despite their
190 widespread clinical usage, these tests can yield subjective and highly variable findings. Due to the
191 abundance and variety of terms used in the literature related to methods and techniques of
192 measurements, word count has necessitated that this document describes only the most frequently
193 published, or methods and techniques using that particular tool in common clinical usage.

194

195 With these limitations in mind, we recommend rating of PFM symptoms as present or absent; if
196 present, a severity and/or bother scale can be added to aid re-assessment in response to an intervention.
197 Some of the signs and investigations terms have rating scales associated with their method and these
198 should be used; if not, we recommend that assessors employ linear measurements (mm/cm) or specify
199 ISI international units of measurement (e.g. s=seconds) where applicable to aid objectivity of the
200 assessment method. If ‘normal’ observations or values are not known, we recommend avoidance of
201 the term ‘abnormal’ or suggestion of pathology or disorder, as this cannot be confirmed with current
202 knowledge. When using assessment methods which measure on a continuous scale but lack reference
203 data of a ‘normal’ value, the terms ‘increased’/‘elevated’/‘higher’/‘faster’, or
204 ‘decreased’/‘reduced’/‘lower’/‘slower’ may be used as this is the limit of our certainty at this point in
205 time. Nevertheless, we acknowledge the subjectivity of these relative rating terms.

206

207 **SECTION 1: SYMPTOMS**

208 This section lists symptoms a patient may use to describe a sensation which could be related to a
209 disorder of PFM structure or function. We recommend the assessor accurately documents the term the
210 patient uses to describe the symptom, rather than an assessor-interpreted term, as symptoms may be
211 used as a patient-reported outcome. A patient-reported outcome is any report of the status of a patient's
212 health condition that comes directly from the patient, without interpretation of the patient's response
213 by an assessor ^(8,9).

214

215 Pelvic floor muscle-related symptoms are divided into sensory and motor categories. Pelvic floor
216 muscle-related symptoms may co-exist with symptoms of pelvic floor disorders such as urinary
217 incontinence, voiding dysfunction, faecal incontinence, defecatory dysfunction, sexual dysfunction or
218 pelvic organ prolapse, as well as co-exist with other disorders of neuro-musculo-skeletal structures in
219 the pelvis or spine FN1.1: the assessor should document the patient’s symptoms and identify which of

220 these s/he considers to be related to the PFM. Examples are provided of words a patient may use to
221 describe their symptoms to the assessor. These words are not specific to neural or myofascial structures
222 in the PFM – they are generic and may be used by a patient to describe altered sensation in any body
223 part – and are therefore not different to standard definitions of these terms in English dictionaries. For
224 this reason, definitions are not provided for these terms in this document, as they are not PFM-specific.
225 The likely exception is the term ‘wind’, which is defined below. In addition to documenting the
226 patient’s symptom (term) and any other descriptors the patient uses to describe the symptom, the
227 assessor documents the perceived location, frequency of occurrence, severity, distress, bother or
228 impact of these symptoms to the patient.

229

230 **1.1 PFM sensory symptoms:** patient terms may include numbness, reduced feeling, decreased
231 sensation, tingling, pins and needles, sensitivity/hypersensitivity, or increased or unusual sensation
232 in the region the patient perceives to be related to the PFM. Terms used to describe painful
233 symptoms may include pain, tender, ache, burning or discomfort in the region the patient perceives
234 to be related to the PFM; use of existing descriptors in published scales⁽¹⁰⁾ is recommended.

235 **1.2 PFM motor symptoms:** patient terms may include loose, lax, gaping, sagging, open, weak,
236 bulging, heaviness, full, loss of control, or difficulty to relax, tight, tense, narrow or constricted. A
237 patient may describe ‘wind’ as a noise or passage of gas.

238 **1.2.1 Vaginal wind:** an involuntary passage of odourless air through the vagina, which is often
239 audible and/or sensible, and usually associated with a change in posture (**CHANGED**)^(11,12). FN1.2
240 This may occur when legs are abducted and a change of position occurs and during times of low
241 estrogen (e.g. breast-feeding).

242 **1.2.2 Anal wind:** FN1.3 complaint of involuntary loss of flatus (gas). (**NEW**)

243

244 Following the assessment of a patient's symptom(s), the assessor will formulate provisional
245 differential diagnoses which will be refined following the clinical examination.

FN1.1 For complete assessment, include as indicated: posture, abdominal, spinal, functional.

FN1.2 'Vaginal flatus' is the term used by Sultan⁽¹¹⁾ however Neels⁽¹³⁾ distinguishes vaginal 'wind' from vaginal 'flatus'; assigning the term flatus to wind that is passed through the vagina due to an enterovaginal fistula. This type of 'vaginal wind' will not be odourless. The term 'vaginal flatus' is more likely to be used by the clinician, not the patient.

FN1.3 This symptom is called 'flatus incontinence' by Sultan et al⁽¹¹⁾.

246

247 **SECTION 2: SIGNS**

248 Signs are elicited from the clinical examination, which includes visual observation, physical inspection
249 and simple tests FN2.1. The majority of PFM clinical signs are tested using digital palpation. The term
250 ‘palpation’ (latin origin: *palpare*) means to touch gently or to use the fingers or hands to examine⁽¹⁴⁾.
251 Palpation allows the assessor to feel the texture, size, consistency and location of certain body parts
252 with the hands, or in the case of PFM assessment, with the fingers or finger-tips FN2.2. Due to the
253 inherent subjective nature of visual and digital assessment, many of these characteristics and properties
254 of the PFM are more accurately assessed using investigations. While some terms will be defined in
255 signs, the measurement of that term may be better done in investigations. If an assessor does not have
256 access to investigations, findings from signs may be used to guide practice, however subsequent
257 research may cast doubt on the certainty of findings from signs.

258

259 There are several aspects for the assessor to be aware of during the clinical assessment which apply to
260 all measured aspects of PFM function, as variations in the examination conditions or maneuvers may
261 alter the results of the test and reduce the certainty of the finding. These are listed in Box 1. We
262 recommend all of these aspects should be reported by assessors to enable reproducibility of assessment.
263 Akin to published checklists for exercise prescription⁽¹⁵⁾, checklists of clinical assessment may
264 improve completeness and quality of research reports.

265

266 Box 1: Checklist of PFM clinical assessment, applicable to signs and investigations

Aspect to standardize	Details to record
1. Patient’s body position for the PFM assessment.	<ul style="list-style-type: none">• lying or upright• if lying, hip/knee flexion, supine, side-lying or lithotomy

		<ul style="list-style-type: none"> • number of pillows, +/- support from assessor's body • bladder empty or not.
2.	<p>Testing of left and right sides of PFM.</p> <p>Symmetry: A measure of comparability of resting tone or shape between left and right sides of the muscle. If examining in side-lying, there will be a gravity effect and the dependent side may have a different feel to the upper side and appear as asymmetrical. This may affect assessor perception of PFM resting tone.</p>	<p>Record if symmetry / asymmetry is present at rest and on activity (contraction / relaxation). Rate as:</p> <ul style="list-style-type: none"> • symmetry between left and right (on a particular aspect/parameter) • asymmetry present. Identify what aspect/parameter is asymmetrical, e.g. tone, L<R⁽¹⁶⁾.
3.	<p>Amount of pressure (light / moderate / strong) applied during digital palpation tests. Particular care is required when undertaking a PFM assessment in the presence of pelvic floor pain, however even in an asymptomatic individual, the assessor may provoke pain or discomfort due to undue pressure applied during palpation or application of an instrument.</p>	<ul style="list-style-type: none"> • if discomfort or pain is provoked, note pain location, intensity, duration (transient or persistent), if it reproduces the pain the patient complains of, and if referral of pain occurs to other locations.

4.	Number of digits (and which digit) used during digital palpation.	<ul style="list-style-type: none"> • for single digit examination (<i>PV</i> or <i>PR</i>), usually the index finger is used • for 2-digit examination (<i>PV</i>), usually the index and middle digits are used.
5.	Orientation (e.g. lateral placement or posterior midline) and depth of examining finger(s) during internal digital palpation examination FN2.3.	<ul style="list-style-type: none"> • the examining finger must be as close as possible to the PFM tissue in order to assess PFM response. • when performing a <i>PV</i> examination, assessor decision as to which side or midline to examine will be determined by lumen capacity, presence of tenderness or defect and presence of firm stool within the rectum • when performing a <i>PR</i> examination, external anal sphincter and puborectalis strength should be assessed separately • record depth of insertion of examining finger for differential assessment of perineal vs levator ani muscle layers. Further identification of individual muscles is not possible in all individuals.
6.	Instruction to perform a maximum voluntary contraction (MVC).	<ul style="list-style-type: none"> • provide details of the instruction (wording, number of repetitions and rest between repetitions) to ensure the test can be reproduced as an MVC.
7.	Contraction of muscles other than those of the pelvic floor.	<ul style="list-style-type: none"> • if this is perceived to influence the PFM assessment, an attempt to minimize this should be made unless the purpose is to assess function of the other muscle.

		<ul style="list-style-type: none"> List specific muscle, such as abdominal, hip adductor, etc.
--	--	---

267 Abbreviations: PFM, pelvic floor muscle(s); L, left; R, right; *PV*, *per vaginam*; *PR*, *per rectum*; MVC,
 268 maximum voluntary contraction.

269

270 This section divides the clinical examination into an external PP assessment and an internal *PV* or *PR*
 271 assessment. The order of examination for PP assessment is visual observation before digital palpation.

272 The full description of each term appears in the subsequent tables and text. Not all tests may be
 273 applicable for each patient; the decision to perform a test should be based upon clinical judgement.

274

275

276 **2.1 External assessment per perineum**

277 **Visual observation:** all terms related to the visual observation per perineum under different PFM
 278 states (at rest, on contraction and with raised intra-abdominal pressure [IAP]) are listed and defined
 279 in Table 2.

280

281 Table 2. External assessment *per perineum*: visual observation.

Tests of visual observation <i>per perineum</i> at rest	
Test	Rating
2.1.1 Perineal skin assessment: assessment of the perineal skin to note presence of: scars, lesions (e.g. fissure), trophic changes / atrophy, color, erythema, swelling and other conditions which could affect the function of the PFM. (NEW)	<ul style="list-style-type: none"> normal skin altered (detail the observation including extent of alteration)

<p>2.1.2 Perineal body length (f): distance from posterior margin of vestibule to anterior anal verge⁽¹⁸⁾.</p>	<ul style="list-style-type: none"> state if < or > 3cm^(19,20)
<p>2.1.3 Perineal body position at rest: relationship of the position of the perineal body to ischial tuberosities FN2.4. (NEW). Palpate ischial tuberosity and visually estimate the relationship.</p>	<ul style="list-style-type: none"> 2.1.3.1 Descended perineum: perineal body rests below the plane of the ischial tuberosities⁽²³⁾ (NEW) normal: at or slightly above the level of the ischial tuberosities elevated: significantly indrawn perineum at rest
<p>2.1.4 Introital gaping: opening, or non-coaptation of vagina at rest. (NEW) If the introitus is not visible at rest the labia may need to be parted</p>	<ul style="list-style-type: none"> present absent
<p>2.1.5 Keyhole deformity at anus: characteristic posterior midline furrow deformity. This complication is seen when the anus is inspected by gently retracting the buttocks laterally. The anus is no longer slit-like, but appears in shape like a keyhole⁽²⁵⁾. (NEW)</p>	<ul style="list-style-type: none"> present note location of deformity with reference to a clock-face (where 12 o'clock is anterior/ventral) absent
<p>2.1.6 Anal gaping: non-coaptation of anal mucosa at rest⁽¹¹⁾.</p>	<ul style="list-style-type: none"> present note location of deformity with reference to a clock-face absent
<p>Tests of visual observation <i>per perineum</i> with a PFM contraction</p>	
<p>2.1.7 Voluntary contraction of the PFM: self-initiated activation of the PFM. (CHANGED)⁽²⁶⁾</p>	<ul style="list-style-type: none"> present uncertain

<p>Contraction of the bulbospongiosus / bulbocavernosus, ischiocavernosus, transverse perineii muscles may be observed FN2.5. The assessor may need to gently move the external genitalia (parting of the labia, lifting of the scrotum to one side) to effectively visualize the perineal response.</p>	<ul style="list-style-type: none"> • absent • Response can be further described according to perineal movement observed: <ul style="list-style-type: none"> • 2.1.7.1 Perineal elevation: inward (ventrocephalad) movement of the vulva (<i>f</i>), perineum, and anus^(11,27) = normal finding • no change • sex-specific changes on perineal elevation: <ul style="list-style-type: none"> ○ <i>f</i>: closure of the urethral meatus ('wink'); a clitoral 'nod' ○ <i>m</i>: closure of the anus, cephalad testicular lift and penile retraction (the shaft of the penis draws in FN2.6)⁽²⁸⁻³⁰⁾. • 2.1.7.2 Perineal descent: dorsocaudal movement of the perineum, or anus 1 cm or greater beyond resting level (CHANGED)⁽²⁷⁾ FN2.7
<p>2.1.8 Relaxation of the PFM: return of the perineum to its original resting position following the voluntary contraction (NEW)</p>	<p>If present, rate as:</p> <ul style="list-style-type: none"> • yes: full relaxation visible directly after instruction; normal finding⁽¹⁶⁾

	<ul style="list-style-type: none"> • partial or delayed relaxation⁽¹⁶⁾ • 2.1.8.1 Non-relaxing PFM: no relaxation visualized of the PFM (CHANGED)⁽²⁶⁾ FN2.8.
Tests of visual observation <i>per perineum</i> with an increase in intra-abdominal pressure (IAP)	
<p>2.1.9 Perineal movement with a sustained increase in IAP: direction of perineal movement during a sustained effort FN2.9. (NEW). As there may be a difference in PFM response to bearing down <i>versus</i> valsalva⁽³¹⁾, it is important to state exact test instruction depending on the test, as the observed response may vary.</p> <ul style="list-style-type: none"> • 2.1.9.1 Valsalva: Forceful exhalation against a closed mouth, glottis and nose⁽³¹⁾. (NEW) Valsalva has been shown to result in an increase in IAP and usually an increase in PFM activation⁽³¹⁾. • 2.1.9.2 Bearing down (as if defecating): a strain or push, which results in an increase in IAP which exerts a downward pressure, usually accompanied by PFM relaxation. (NEW) 	<ul style="list-style-type: none"> • perineal elevation (see 2.1.7.1) FN2.10 • no change • perineal descent (see 2.1.7.2) • 2.1.9.3 Excessive perineal descent with bearing down: movement of the perineum 3 cm or more below resting position⁽²¹⁾ FN2.11. (NEW)
<p>2.1.10 Perineal movement with rapid increase in IAP: direction of perineal movement during a rapid increase in IAP such as coughing, lifting, throwing. (NEW) Clarify if the patient is instructed to contract PFM before cough in order to differentiate voluntary</p>	<ul style="list-style-type: none"> • perineal elevation (see 2.1.7.1)⁽²⁶⁾ FN2.12, FN2.13 • May be due to:

(learned) response from an involuntary response (un-learned).	<ul style="list-style-type: none"> • voluntary contraction (see 2.1.19) – pre-contraction may be a learned response FN2.14 • 2.1.10.1 Involuntary contraction: a contraction which occurs reflexively or automatically, without volition or conscious control. Observe this response before instructing in a voluntary pre-contraction in order to differentiate from the voluntary pre-contraction response. (CHANGED)⁽²⁶⁾ • no change • perineal descent FN2.15
---	--

Abbreviations: *f*, female; *m*, male; PFM, pelvic floor muscles; IAP, intra-abdominal pressure

282

283 **Digital palpation:** all terms related to digital palpation *per perineum* under different PFM states (at
 284 rest, on contraction and with raised IAP) are listed and defined in Table 3.

285

286 Table 3. External assessment *per perineum*: digital palpation

Tests of digital palpation <i>per perineum</i> at rest	
Test	Rating
2.1.11 Sensation: Test for presence, absence or altered quality of sensation in dermatomal	<ul style="list-style-type: none"> • allodynic, anaesthetic, dysesthetic, hyperalgesic, hyperesthetic,

<p>distributions especially S2-4. May include light touch, blunt, sharp, pain, cold, vibration modalities. (NEW)</p>	<p>hypoalgesic, hypoesthetic, paresthetic, neuralgic⁽³⁴⁾.</p>
<p>2.1.12 Perineal scarring: presence of scar tissue on perineum. (NEW). Using a finger-tip, attempt to slide the scar in all directions. Assess for adhesion or lack of skin mobility over underlying tissue FN2.16.</p>	<ul style="list-style-type: none"> • present • degree of healing • location of scar in relation to vulva/scrotum or anus • location of adhesion • extent/magnitude of scar mobility⁽³⁵⁾. • absent
<p>2.1.13 Tone: state of the muscle, usually defined by its resting tension, clinically determined by resistance to passive movement⁽²⁷⁾. The recommended position of the examining digit(s) is to place the palmar surface of the examining finger on the ischiocavernosus, bulbospongiosus (<i>f</i>) / bulbocavernosus (<i>m</i>) or transverse perineal muscle belly at the thickest portion of the muscle belly, <i>per perineum</i>. Pressure or stretch is applied perpendicular to the muscle fibres to assess tone. Tone is described in more detail in 2.2.3.</p>	<ul style="list-style-type: none"> • normal • decreased tone (see 2.2.3.4) • increased tone (see 2.2.3.5)
<p>2.1.14 Tenderness: sensation of discomfort with or without pain; discomfort elicited through palpation of any tissue indicates unusual sensitivity to pressure or touch⁽²⁷⁾. May be generalised within a muscle.</p>	<ul style="list-style-type: none"> • note location of pressure application • note location of pain (where pressure applied, or if pain referral present, note location of pain referral)

<p>2.1.14.1 Tender point: area of localised tenderness occurring in muscle, muscle-tendon junction, bursa, or fat pad (CHANGED)⁽²⁷⁾ FN2.17.</p>	<ul style="list-style-type: none"> • rate severity of pain on a numeric rating scale (NRS) 0 – 10⁽³⁷⁾
<p>2.1.15 Pudental nerve neurodynamics: neurodynamic assessment evaluates the length and mobility of the nerve in order to assess neurogenic origin of pain⁽³⁸⁾ (NEW). Tension is applied to the nerve or specific component of the nerve by lengthening the nerve or by distracting imposing tissues⁽³⁸⁾. Specific components of the pudental nerve can be put under tension such as the inferior rectal branch, the dorsal branch and the perineal branch.</p>	<ul style="list-style-type: none"> • positive: if pain, sensation of burning or stabbing are experienced in the distribution of the nerve. This assessment can be uncomfortable in asymptomatic individuals, however reproduction of patient's pain is suggestive of a neurogenic origin of pain • negative
<p>2.1.16 Cotton swab test (f) FN2.18: a test for vestibular tissue sensitivity. (NEW) The test is performed with a cotton swab moistened with water or lubricating gel. Gentle pressure is applied to the following areas of the vaginal vestibule FN2.19 in random order: 12:00, and quadrants 12-3:00, 3:00-6:00, 6:00-9:00, 9:00-12:00 FN2.20.</p>	<ul style="list-style-type: none"> • positive if gentle pressure reproduces patient's pain • report location of pain and severity on NRS 0 – 10⁽³⁷⁾ • negative
<p>Tests of digital palpation <i>per perineum</i> for sacral reflex function</p>	
<p>2.1.17 Sacral reflex testing: a measure of the involuntary function of sacral nerves. (CHANGED)⁽¹²⁾ FN2.21 Tests are described below.</p>	<ul style="list-style-type: none"> • present: observation of anal sphincter contraction. Indicative of intact spinal reflex arcs (S2–S4 spinal segments) with afferent and efferent nerves through the pudental nerve⁽⁴¹⁾

	<ul style="list-style-type: none"> absent: no sphincter activity
<p>2.1.17.1 Bulbocavernosus reflex (f): A reflex contraction of the anal sphincter and bulbocavernosus in response to squeezing the clitoris (CHANGED)⁽¹²⁾.</p>	<ul style="list-style-type: none"> present absent
<p>2.1.17.2 Bulbospongiosus reflex (m): a reflex contraction of the striated muscles of the pelvic floor (anal sphincter) including bulbospongiosus muscles that occurs in response to various stimuli in the perineum or genitalia. Most commonly tested by placing a finger in the rectum and then squeezing the glans penis⁽⁴²⁾.</p>	<ul style="list-style-type: none"> present absent
<p>2.1.17.3 Anal reflex: a reflex contraction of the anal sphincter in response to a painful pin prick delivered to the perianal skin⁽¹²⁾. (CHANGED) FN2.22</p>	<ul style="list-style-type: none"> present absent
Tests of digital palpation <i>per perineum</i> with PFM contraction FN2.23	
<p>2.1.18 Voluntary contraction of the PFM: self-initiated activation of the PFM (same term as 2.1.7). Each of the bulbospongiosus / bulbocavernosus, ischiocavernosus and transverse perineii muscles may be palpated separately. The assessor may need to gently move the external genitalia (parting of the labia, lifting of the scrotum to one side) to effectively palpate the perineal response.</p>	<ul style="list-style-type: none"> present absent uncertain

Abbreviations: PFM, pelvic floor muscles; *f*, female; *m*, male; NRS, numeric rating scale.

287

288 **2.2 Internal assessment *per vaginam* (PV) or *per rectum* (PR) by digital palpation**

289 Resting state: The following terms (in Tables 4 and 5) are used to define, describe and rate PFM
290 assessment in the resting state *per vaginam* (PV) or *per rectum* (PR) by digital palpation. Terms
291 related to muscle tone are expanded upon in subsequent text in order to provide greater explanation
292 of the term definitions and descriptions.

293

294 Table 4. Tests of digital palpation *per vaginam* / *per rectum*, resting state

Test	Rating
<p>2.2.1 Sensation: test for presence, absence or altered quality of light touch sensation as for 2.1.12.</p>	<ul style="list-style-type: none"> • present • absent • altered: increased or decreased
<p>2.2.2 Presence of scarring: presence of scar tissue along vaginal walls or apex. (NEW). Using a finger-tip, attempt to slide the scar in all directions. Assess for adhesion or lack of mucosal / vaginal wall mobility over underlying tissue. FN2.24</p>	<ul style="list-style-type: none"> • present • location of adhesion • degree of healing • extent/magnitude amount of scar mobility • absent
<p>2.2.3 Tone: see 2.1.13. The recommended position of the examining digit(s) is to place the palmar surface of the examining finger on the levator ani, PV or PR. Pressure or stretch is applied perpendicular to the muscle fibres to assess tone.</p>	<ul style="list-style-type: none"> • normal • decreased tone (see 2.2.3.4) • increased tone (see 2.2.3.5)

Further details regarding terminology and assessment of muscle tone are provided in text section 2.2.3 below.	
2.2.4 Fasciculation: individual brief twitches in a muscle. They may occur at rest or after muscle contraction and may last several minutes ^(27,43) .	<ul style="list-style-type: none"> • present • absent
2.2.5 Tenderness: see 2.1.15 and 2.1.15.1	See 2.1.15 and 2.1.15.1
2.2.6 Pudendal nerve provocation test: palpation of the pudendal nerve to reproduce patient’s pain if entrapment is suspected. The nerve may be palpated at the ischial spine, sacrospinous and sacrotuberous ligaments, or pudendal canal. ^(44,45) . (NEW)	<ul style="list-style-type: none"> • positive (pain response) • negative
<i>Per rectum only:</i>	
2.2.7 Digital rectal examination (DRE) FN2.25: palpatory examination of the anorectal tissues FN2.26. (CHANGED) ⁽⁴²⁾	
2.2.8 Palpable anal sphincter gap (PR): a clear “gap” in the anal sphincter on digital examination indicates an anal sphincter tear. (CHANGED) ⁽¹¹⁾ FN2.27	<ul style="list-style-type: none"> • present • absent • note location

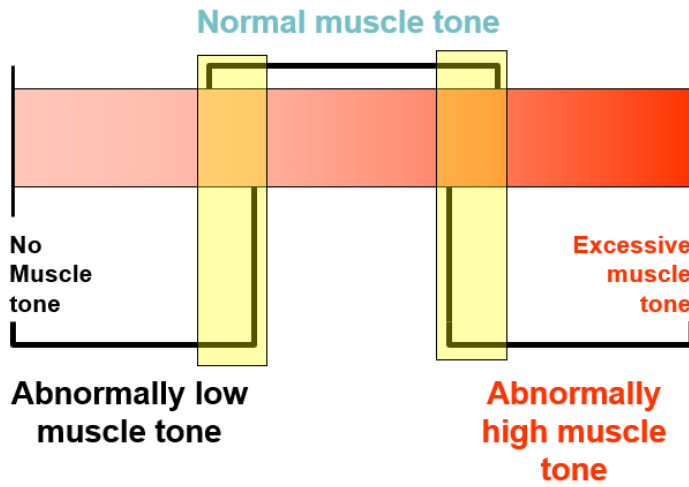
295 Abbreviations: NRS, numeric rating scale; PR, *per rectum*

296

297 **2.2.3 Muscle tone**

298 Tone exists on a continuum, from hypotonicity (low tone) to hypertonicity (high tone). Normal
299 tone may overlap with abnormally decreased muscle tone or abnormally increased muscle tone
300 at either end of the tone spectrum, as illustrated in Figure 2. Tone is a dynamic physiological
301 state modulated by many inputs: spinal cord, cortex, brainstem relays, stretch reflexes and

302 cutaneous receptors, visceromotor reflex pathways, emotions and pain (anticipation or
 303 experience of pain).



304

305 Figure 2: Spectrum of muscle tone (adapted from Allen & Widener 2009)⁽⁴⁷⁾

306

307 We recommend terms to indicate alterations to normal tone are differentiated according to the
 308 presence or absence of a neurological disorder, as illustrated in Figure 3. Abnormal tone related
 309 to a neurological disorder (hypotonicity, hypertonicity, dystonia) should not be used when
 310 describing PFM tone in a patient who does not have a diagnosed neurological disorder.

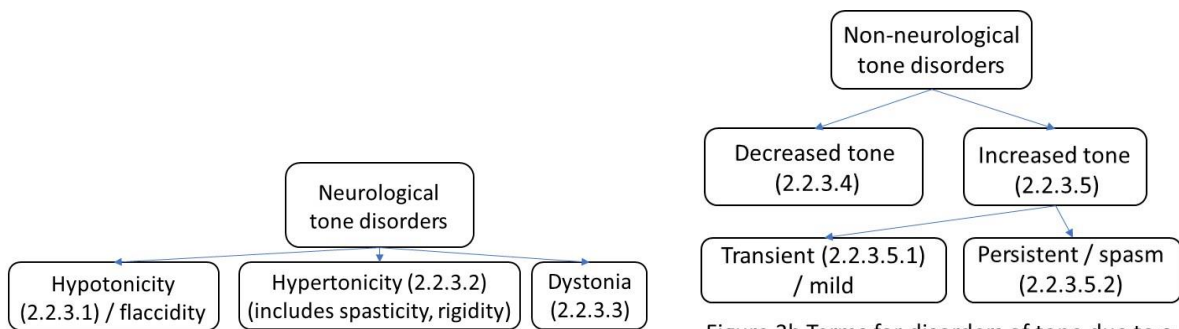


Figure 3a Terms for disorders of tone due to a neurological disorder

Figure 3b Terms for disorders of tone due to a non-neurological disorder

311

312 Figure 3 Terms for disorders of tone due to a neurological disorder (3a) and a non-neurological
 313 disorder (3b).

314

315 Physiological basis of muscle tone

316 Muscle tone has two components: the physiological contractile component, created by the
317 activation of motor units, and the non-contractile viscoelastic, or biomechanical component. The
318 active component (EMG activity) of tone is the component that is related to the neural drive,
319 therefore it is subject to variation and ongoing adjustment. The viscoelastic component is
320 independent of neural activity and reflects the passive physical properties of the viscoelastic
321 tension of the muscle tissues (e.g. the extensibility of actin-myosin cross-bridges); non-
322 contractile cytoskeleton proteins and connective tissues surrounding the entire muscle
323 (epimysium), muscle fascicle (perimysium), and muscle fiber (endomysium) as well as the
324 osmotic pressure of the cells. Alterations in either the active or passive component can affect the
325 resting tone; digital palpation cannot differentiate between these elements however
326 investigations that combine EMG with another measure that assesses passive properties can
327 identify specific components.

328

329 A localised area of increased tone within a muscle may be referred to as a taut band⁽⁴⁸⁾. A trigger
330 point is considered to be a tender nodule within a taut band⁽⁴⁸⁾. The trigger point is considered
331 by some authors to be part of the active component of tone⁽⁴⁸⁾ given the local disturbance in
332 electrical activity, and by others as a separate category distinct from the active or passive
333 components of tone⁽⁴⁹⁾. Given the uncertainty about the characterisation of a trigger point^(50,51),
334 we propose describing palpatory findings by use of the terms ‘tender point’ (2.1.15.1) and
335 ‘increased tone’ (2.2.3.4) if both observations coincide at the tested site, or use only ‘tender
336 point’ (2.1.15.1) or ‘increased tone’ (2.2.3.4) if only one of those signs is observed at the tested
337 site.

338

339 Assessment and rating

340 Tone can be assessed by application of digital site-specific compression and/or overall muscle
341 stretch. Digital palpation is inherently subjective and may be limited by pain provocation.
342 Several scales to quantify resting PFM tone in the absence of a neurological disorder have been
343 proposed using either a 3-point^(52,53), 6-point⁽⁵⁴⁾ or 7-point⁽⁵⁵⁾ scale.

344

345 Definitions and descriptions

346 **2.2.3.1 Hypotonicity:** a decrease in muscle tone in a patient **with** a neurological disorder. It
347 may be due to a lower motor neuron or a muscle disorder. The term flaccidity⁽⁵⁶⁾ is often used
348 interchangeably. (NEW)

349 **2.2.3.2 Hypertonicity:** an increase in muscle tone in a patient **with** a neurological disorder.
350 It may be due to an upper motor neuron or extrapyramidal lesion, which in turn may lead to
351 spasticity⁽⁵⁶⁾ or rigidity⁽⁵⁶⁾ (NEW)

352 **2.2.3.3 Dystonia:** a disorder characterized by abnormalities of muscle tone and
353 movements/postures in a patient **with** a neurological disorder⁽⁵⁷⁾. It is often due to damage to
354 the basal ganglia or other brain regions that control movement. (NEW)

355 **2.2.3.4 Decreased PFM tone:** a decrease in resting muscle tone in a patient **without** a
356 neurological condition (CHANGED)⁽⁴³⁾

357 **2.2.3.5 Increased PFM tone:** an increase in muscle resting tone in a patient **without** a
358 neurological disorder. (CHANGED)⁽⁴³⁾. Increased tone may occur without patient report of
359 pain.

360 **2.2.3.5.1 Transient increased muscle tone:** Increased muscle tone that decreases with
361 verbal instruction, re-assurance or gentle pressure (NEW). Transient increase in tone may
362 occur at any time during the examination.

363

364 **2.2.3.5.2 Muscle spasm:** persistent contraction of muscle that cannot be reduced
 365 voluntarily^(11,27,43). Spasms may occur at irregular intervals with variable frequency and
 366 extent, and over time may lead to increased viscoelastic stiffness and shortening in the
 367 muscular and connective tissues FN2.28, FN2.29.

368
 369 **Resting state *per vaginam* (PV) only (f):** terms related to digital palpation of the vaginal tissues
 370 with the PFMs in a resting state are listed in Table 5.

371

372 Table 5 Tests of digital palpation *per vaginam* only with the PFM in a resting state.

Test	Rating
<p>2.2.9 Flexibility of the vaginal opening: the capacity of the vaginal opening to expand in response to stretching. (NEW) Assessed by separating index and middle finger in the medio-lateral direction⁽⁵⁸⁾. Digital assessment of the vaginal opening is likely to represent the width of the levator hiatus FN2.30.</p>	<ul style="list-style-type: none"> • estimate the number of finger widths between the muscle bellies • can be converted to cm width for the recording from that assessor.
<p>2.2.10 Levator injury/avulsion: a discontinuity of the levator muscle at its attachment to the inferior pubic ramus. (NEW) Discontinuity may represent a partial tear, full tear or thinning.</p> <p>Test for levator injury / avulsion: palpation of levator tissue, by placing finger(s) between the side of the urethra and the edge of the muscle measured on each side. The test is performed at rest and confirmed by asking the patient to</p>	<ul style="list-style-type: none"> • absent: palpable PFM contraction next to the urethra on the inferior pubic ramus • present: a distance of > 3.5 finger widths between the two sides of puborectalis muscle insertion on PFM contraction⁽²⁷⁾ FN2.31. • rate number of finger widths palpable in the gap.

contract and feeling for the edge of the contractile tissue of the levator muscle.	<ul style="list-style-type: none"> • several rating scales exist^(54,59).
--	--

373 Abbreviations: PFM, pelvic floor muscles.

374

375 **Pelvic floor muscle contraction:** the following terms in Table 6 are used in the definition and
 376 the ratings of digital assessment *per vaginam / per rectum* of the PFMs during contraction.

377

378 Table 6 Tests of digital palpation *per vaginam / per rectum* on PFM contraction.

Test	Rating
<p>2.2.11 Voluntary contraction of the PFM: self-initiated activation of the PFM (same term as 2.1.7). A contraction is felt as a tightening, lifting, and squeezing action under the examining finger. Technique:</p> <ul style="list-style-type: none"> • the recommended position of the examining digit(s) to assess levator ani contraction (<i>PV</i>) unilaterally is to place the palmar surface of the examining finger on the lateral levator ani muscle belly surface or 'edge', which may be identified by asking the patient to contract then relax • the recommended position of the examining digit to assess anal sphincter and puborectalis muscle function (<i>PR</i>) is to place the palmar surface of the well-lubricated examining finger at the anal verge initially, wait for relaxation of EAS, then insert 	<p>Presence of contraction may be rated as:</p> <ul style="list-style-type: none"> • no contraction • correct contraction (cephalad and ventral movement) • contraction only with help from other muscles • uncertain • straining⁽⁶¹⁾ <p>Absent: 2.2.11.1 Non-contracting PFM: during palpation there is no palpable voluntary or involuntary contraction of the PFM⁽²⁶⁾ FN2.32.</p>

<p>gently along the posterior wall of the anal canal⁽⁶⁰⁾.</p> <p>Once anal sphincter function is assessed the examining digit remains pressed against the posterior wall and is inserted slowly into the rectum, passing over puborectalis at the anorectal junction.</p>	
<p>2.2.12 Digital muscle test (DMT): a test to evaluate PFM strength (NEW).</p> <p>2.2.12.1 Strength: force-generating capacity of a muscle. Usually expressed as a maximum voluntary contraction measurement (MVC)⁽²⁷⁾. A manual muscle test (MMT) evaluates the strength of a muscle by moving the muscle through its full-range of motion against gravity and then against gravity with resistance⁽¹⁴⁾. However, because joint range of motion is not being assessed in the pelvic floor and PFM examination is performed with a digit, not a hand, the term DMT is preferred. There are more than 25 published DMT scales^(62,63) which provide grade of strength ranging from absence, to weakness to increasing strength.</p>	<ul style="list-style-type: none"> • Commonly used scales include: ICS scale: absent, weak, normal (we propose the word ‘moderate’ instead of normal), or strong⁽²⁶⁾ • modified Oxford grading scale 0-5⁽⁶⁴⁾ • Brink scale⁽⁶⁵⁾ grades 3 components (pressure, displacement, and time) on a scale of 1 to 4 • many others ^(62,63)
<p>2.2.13 Direction of pelvic floor movement: direction of pelvic floor movement during voluntary PFM contraction palpated <i>PV</i> (on the posterior vaginal wall) or <i>PR</i>. (NEW)</p>	<ul style="list-style-type: none"> • pelvic floor elevation: normal finding • pelvic floor descent: palpation of downward movement of the PFM during attempted PFM contraction

	<ul style="list-style-type: none"> no change
<p>2.2.14 Endurance: Muscular endurance refers to the ability of a muscle or muscle group to perform repeated contractions or to maintain a contraction for a predetermined period of time^(66,67). (CHANGED)⁽²⁷⁾</p>	<p>2.2.14.1 Fatigue: a decreased capacity to perform a maximum voluntary muscle action or a series of repetitive contractions. (NEW) Fatigue may occur due to central or peripheral mechanisms⁽⁶⁸⁾. A fatigued muscle is unable to continue working even when the type of activity is changed FN2.33.</p> <p>Record the time at which fatigue starts to occur, or the number of contractions in a row before onset of fatigue.</p>
<p>2.2.14.2 Sustained contraction endurance test: the number of seconds the patient can hold near maximal or maximal PFM contraction. (NEW)</p>	<ul style="list-style-type: none"> record number of seconds contraction is sustained at near maximal or maximal intensity
<p>2.2.14.3 Repeatability of contraction: the ability to repeatedly develop near maximal or maximal force determined by assessing the maximum number of repetitions the patient can perform (CHANGED)⁽²⁷⁾ FN2.34.</p>	<ul style="list-style-type: none"> record number of contractions in a row
<p>2.2.15 Number of rapid contractions performed: the number of repeated, quick MVCs performed (NEW). This can be measured in two ways, according to the instruction:</p> <ol style="list-style-type: none"> number of contractions repeated within a specific duration (i.e. a 10-s period⁽⁵⁾) 	<p>Use the rating appropriate to the instruction:</p> <ol style="list-style-type: none"> record the number of contractions repeated and the duration allowed to perform them

<p>2. the elapsed time to perform a pre-specified number of contractions (e.g. 10-s⁽⁷⁰⁾).</p> <p>A contraction should comprise an ascending and a descending phase with the PFM force returning to the resting state in between. If the maximal force declines, the assessment ceases.</p>	<p>2. specify the exact number of contractions to be repeated and record the number of seconds to completion.</p> <ul style="list-style-type: none"> • qualitative descriptions can include quality and extent of contraction and relaxation phases.
<p>2.2.16 Relaxation post-contraction: return of the PFM to its original resting tone following the voluntary contraction (CHANGED)⁽²⁶⁾ FN2.35. The patient is able to relax the PFM on demand, after a contraction has been performed. Relaxation is felt as a termination of the contraction.</p>	<ul style="list-style-type: none"> • yes: relaxation felt directly after instruction: normal finding • partial or delayed relaxation • no: absent = non-relaxing PFM (see 2.1.8.1).
<p>2.2.17 Co-ordination: the ability to use different parts of the body together smoothly and efficiently⁽²⁷⁾. In the pelvic floor, co-ordination may be an action between PFM and organ function (e.g. PFM relaxation during voiding), PFM and an external environmental event (e.g. movement of a limb) and PFM and a rise in IAP (e.g. PFM contraction prior to a cough). Co-ordination is an aspect of motor control.</p>	<ul style="list-style-type: none"> • present • absent. If absent, describe pattern of incoordination. e.g. paradoxical contraction: the inability to maintain PFM relaxation when it is expected; or lack of PFM contraction when it is expected.
<p>2.2.17.1 Co-contraction: contraction of two or more muscles at the same time⁽²⁷⁾. Co-contraction of muscles can be synergistic (e.g., resulting in an augmentation of motor activity) or it could be counterproductive to normal function (e.g., contraction of antagonistic muscles</p>	<ul style="list-style-type: none"> • if present, identify which muscles are co-contracting, and whether the co-contraction is synergistic or counter-productive FN2.36.

resulting in abnormal movement or training other muscles instead of the targeted ones, e.g., training of gluteal muscles instead of the PFM)⁽²⁷⁾. Activation or inhibition of PFM contraction may be task-dependent.

379 Abbreviations: PFM, pelvic floor muscles; *PV*, *per vaginam*; *PR*, *per rectum*; EAS, external anal
 380 sphincter; DMT, digital muscle test; *f*, female; *m*, male; MVC, maximum voluntary contraction; IAP,
 381 intra-abdominal pressure.

382

383 **Pelvic floor muscle contraction per vaginam (PV) only (f):** terms related to digital palpation
 384 *per vaginam* only (*f*), on PFM contraction are listed in Table 7.

385

386 Table 7. Tests of digital palpation *per vaginam* only (*f*), on PFM contraction ^{FN2.37}.

Test	Rating
<p>2.2.19 Urethral lift: elevation of the urethra in a cephalad direction⁽¹⁶⁾. (NEW) Index finger is placed along the line of the urethra (on the anterior vaginal wall).</p>	<ul style="list-style-type: none"> • yes: urethral lift palpable • no: no urethral lift palpable
<p>2.2.20 Levator closure: movement of right and left muscle bellies closer together during a PFM contraction (palpated on the lateral vaginal wall)⁽¹⁶⁾. (NEW). May be tested unilaterally if bi-digital assessment is uncomfortable for the patient.</p>	<ul style="list-style-type: none"> • yes: levator closure movement palpable • partial / uncertain: some closure movement palpable, but could be un-certain, or asymmetrical • no: no levator closure movement palpable
<p>2.2.21 Levator hiatus size: the size of the levator hiatus measured during maximal</p>	<ul style="list-style-type: none"> • with 2 fingers in the vagina, distance measured in centimeters (converted

<p>contraction by a digital examination⁽⁷¹⁾ FN2.38.</p> <p>(NEW)</p>	<p>approximately from finger widths) during PFM contraction</p> <ul style="list-style-type: none"> • LH transverse: the distance between the left and right muscle bellies just inferior to the pubic bone • LH sagittal: the distance between the back of the pubic symphysis and the midline raphe of the puborectalis⁽⁷¹⁾.
--	--

387 Abbreviations: *PV*, *per vaginam*; LH, levator hiatus.

388

389 **Pelvic floor muscle response to intra-abdominal pressure *per vaginam* or *per rectum***

390 **2.2.22 Direction of PFM movement during sustained increase in IAP:** as per 2.1.9. Specify
 391 task instruction, as response may differ depending on wording. Rate as elevation, no change,
 392 descent (normal finding), excessive descent.

393

394 Following the assessment of a patient's clinical signs, the assessor will formulate a provisional
 395 differential diagnosis which will be refined following the results of the investigations.

FN2.1 Included in the physical examination may be the use of simple tools, such as a pin, cotton wool, reflex hammer etc.

FN2.2 When assessing sensory changes *PV* or *PR*, the clinician needs to determine whether s/he is detecting sensory change in the mucosa (mucosal sensitivity), or the underlying muscle (muscle tenderness) by attempting to differentiate the depth and firmness of palpation.

FN2.3 Depth of insertion of examining finger has been described for *per vaginam* assessment⁽¹⁷⁾.

FN2.4 Visual observation of the exact position maybe influenced by variations in adipose tissue over the ischial tuberosities⁽²¹⁻²⁴⁾.

FN2.5 As the levator ani are likely to be co-contracting with the superficial PFM, the observed response is unlikely to be due to the superficial PFM layer alone, as the levator ani contraction is likely to be contributing to the observed response.

FN2.6 These movements may be observed alongside perineal elevation and may be better visualized in standing than supine. These observations to be checked against movement of the scrotum and the whole penis.

FN2.7 Modification: the word "excessive" has been removed from the previous definition⁽²⁷⁾ as some downward movement of the perineum is normal with coughing or bearing down such as in defecation.

-
- FN2.8 The term ‘non-relaxing PFM’⁽²⁶⁾ was previously used as a diagnosis, however this term describes a sign, and is not recommended to be used as a diagnosis. This sign may be combined with symptoms to inform a clinical diagnosis.
- FN2.9 The term ‘involuntary relaxation’ is not recommended to define perineal movement as it not possible to determine if the downward PFM movement is related to voluntary muscle relaxation or passive elongation of non-contractile tissue.
- FN2.10 Some patients will not allow full relaxation during assessment for fear of releasing gas or urine, therefore may voluntarily contract during this test.
- FN2.11 Adipose tissue at the ischial tuberosities will affect the measurement⁽²¹⁾.
- FN2.12 Perineal elevation with cough is expected but not always present.
- FN2.13 Messelink et al described the response of perineal elevation to a rapid increase in IAP as the test for an involuntary contraction⁽²⁶⁾. However it is not possible to say if this is an involuntary or reflex activation of muscle spindles resulting in a contraction, or a voluntary pre-contraction of the PFM before increased IAP. Strategies may differ or be combined⁽³¹⁾.
- FN2.14 This manoeuvre is also called “the knack”⁽³²⁾.
- FN2.15 A small degree of descent may be normal⁽³³⁾.
- FN2.16 Adherent skin could impact function of PFM beneath the scar.
- FN2.17 Tender points (2.1.15.1) differ from trigger points (see 2.2.3) therefore the terms should not be used interchangeably⁽³⁶⁾.
- FN2.18 This test is also referred to as the "Q Tip test". "Cotton swab" is preferred to avoid proprietary names.
- FN2.19 Excessive pressure could provoke underlying structures (such as the PFM) misleading the report of pain to vestibular tissues.
- FN2.20 Examination tip: in patients with high irritability, it is recommended to test the most severe pain area last to avoid an amplified response due to carry-over irritation as the test progresses^(39,40). In addition if an area provokes increased pain, it is important to wait for the pain to subside before testing other locations.
- FN2.21 This term is listed as a modification of the term in Rogers et al⁽¹²⁾.
- FN2.22 In contrast to the bulbocavernosus reflex the anal reflex is a nociceptive reflex and the correct stimulus is painful. If a single stimulus does not activate the reflex, several pricks in a fast sequence should be delivered. It is often difficult to elicit in the elderly, and it should not be declared absent if only a single stimulus is used. A “voluntary” movement away from the (painful) stimulus (pin prick) can usually be interpreted correctly. The patient should be told that painful stimuli are going to be delivered, and usually they can “keep still” and only the reflex contraction of the anal sphincter is observed. It is often absent even in patients without a neural lesion.
- FN2.23 Some of the tests performed in the external examination section may be repeated during the internal examination.
- FN2.24 Adherent skin could impact function of PFM beneath the scar.
- FN2.25 Despite the name (DRE), the purpose of the examination is usually to assess anal canal tissue, not rectal tissue.
- FN2.26 DRE may be less useful in male urinary dysfunctions where the urethral sphincter, inaccessible to DRE, has a more important role⁽⁴⁶⁾.
- FN2.27 An assessment can be made of a palpable anal sphincter gap to assess if there has been previous obstetric or surgical damage⁽¹¹⁾.
- FN2.28 Terms such as short or elevated PFM may not be discernible via digital palpation and are therefore not recommended as sign terms.
- FN2.29 If the spasm is painful, this is usually described as a muscle cramp.
- FN2.30 Levator hiatus may be better measured with instruments (see Section 3).
- FN2.31 <3.5cm may represent a partial avulsion, however digital palpation cannot reliably determine this distance of discontinuity
- FN2.32 This term is referring to a sign and not recommended to be used as a diagnosis. This sign may be combined with symptoms to inform a clinical diagnosis.

FN2.33 Endurance training can delay the onset of fatigue⁽⁶⁹⁾.

FN2.34 Modification from Bo et al⁽²⁷⁾: removal of “at a given percentage of 1 RM” as definition already states “near maximal or maximal force”.

FN2.35 This can only be graded if the patient is able to generate a PFM contraction.

FN2.36 Antagonistic contraction has not been included in this document as there is not a muscle whose action counteracts the action of the PFM.

FN2.37 These tests are likely to produce more accurate results if measured using ultrasound imaging.

FN2.38 This test was performed in patients with POP; the same technique may be uncomfortable in women with pelvic floor pain or increased tone.

396

397 **SECTION 3: INVESTIGATIONS**

398 An investigation is part of the differential diagnostic decision-making process. A PFM investigation
399 is the measurement of the morphometry or function of the PFMs using mechanical or technological
400 methods. The findings may be considered more accurate than findings from a clinical evaluation which
401 relies on digital palpation. Some points to note regarding PFM investigations that should be considered
402 in clinical and research application and interpretation of the finding: all devices are different and may
403 not give the same information of a specific PFM physiological parameter or function. In addition,
404 device specifications and analysis software options influence both the availability and measurement of
405 PFM parameters^(72,73), the size and shape of a probe / sensor / electrode / transducer also influence the
406 interpretation of findings⁽⁷²⁻⁷⁴⁾ and raw values may need to be normalised. New devices to measure
407 PFM properties may become available in the near future which do not fit the existing categories
408 entirely, and new categories may need to be added to this living document.

409

410 **3.1 Dynamometry:** an investigation that measures both muscle power and force. **(CHANGED).**

411 Both active (contractile) and passive (non-contractile) forces can be detected.

412 **3.1.a Intra-vaginal PFM dynamometry:** Measurement of PFM resting and contractile forces
413 using strain gauges mounted on a speculum (a dynamometer), which is inserted into the
414 vagina⁽⁷⁵⁾ **(CHANGED).**

415 Several PFM dynamometers have been developed to assess the PFM function in women⁽⁷⁶⁻⁸⁴⁾..

416 Different configurations have been proposed in terms of the number, shape and the sizes of the
417 branches, the force vector recorded (i.e. antero-posterior, latero-lateral or multi-directional forces)
418 and the device specifications (e.g configuration of strain gauges to avoid a lever-arm effect – the
419 influence of the force location in regards to the gauges). In some dynamometers, the branches can
420 be separated at a constant speed either manually or with a motorised unit to assess the passive

421 properties during dynamic stretches^(81,85). Elastometry is a type of intra-vaginal PFM dynamometer
 422 used for this specific application of evaluating the passive properties during dynamic stretches⁽⁸¹⁾.
 423
 424 Table 8 describes the most frequent parameters measured with intra-vaginal dynamometers as well
 425 as their definitions, specifications and findings. Parameters can be assessed at different fixed vaginal
 426 apertures or during stretching (i.e. while imposing an elongation to the tissues by separating the
 427 speculum branches)^(81,84). The parameters measured with the dynamometer alone reflect the
 428 summative contribution of the active and passive components of tone. When combined with EMG,
 429 it enables the assessment of the differential contributions of tone components⁽⁸⁶⁾, i.e. during passive
 430 stretch of the PFM, concurrent EMG activity detects any electrogenic contributions. The passive
 431 component can then be identified when the EMG remains negligible^(86,87).

432
 433 Table 8. Parameters and findings evaluated with intravaginal dynamometry

Parameters, specifications (units of measure) and measurement processes	Outputs and interpretation of findings
<i>a). Parameters assessed at rest</i>	
3.1.1 Passive forces: the average forces in N recorded at rest ⁽⁸⁴⁾ . (NEW) Specify: - opening (distance between the two branches e.g minimal opening, selected opening or maximal opening) - while stretching (dynamic opening)	The finding is the resting forces of the PFM's which are indicative of PFM tone i.e. the summative contribution of the active and passive components of tone.
3.1.2 Maximal aperture: the maximal vaginal opening in mm or cm of the dynamometer branches, without provoking a pain response ⁽⁸⁶⁾ . (NEW)	This aperture can be used to evaluate the flexibility $_{FN3.1}$ of the PFM's.

<p>3.1.3 Viscoelastic stress relaxation during a static (sustained) stretch: the percentage loss in passive force during the application of a steady stretch over a prolonged period (e.g. 1 min)^(85,88). (NEW)</p>	<p>Higher percentage of force decline is indicative of an enhanced viscoelastic stress relaxation response and muscle relaxation. This could be useful in quantifying tissue relaxation following stretching or lower force decline associated with strength training⁽⁸⁸⁾.</p>
<p><i>b). Parameters assessed at rest during dynamic stretching:</i></p> <p>Dynamic stretches are applied by repeatedly separating the speculum branches at a constant speed until maximal vaginal aperture (lengthening phase) and then, closing back to the minimal aperture (shortening phase).</p>	
<p>3.1.4 Stiffness: the resistance to deformation. Passive elastic stiffness is defined as the ratio of the change in the passive resistance or passive force (ΔF) to the change in the length displacement (ΔL) or $\Delta F / \Delta L$ (N/mm)^(27,43,75)</p> <p>FN3.2. Passive elastic stiffness should be computed for specific vaginal apertures^(81,84).</p>	<p>The higher the N/mm value, the stiffer the muscle. This is a physiological property of muscle which contributes to the overall measurement of tone.</p>
<p>3.1.5 Compliance: the reciprocal of muscle stiffness (mm/N)⁽⁴³⁾. (NEW)</p>	<p>The higher the mm/N, the more compliant the tissue.</p>
<p>3.1.6 Hysteresis: the area between the lengthening and shortening curves (N x mm). It corresponds to the loss of energy associated with lengthening of viscoelastic tissues⁽⁸⁵⁾. (NEW)</p>	<p>Increased area indicates higher energy dissipated.</p>
<p><i>c). Parameters evaluating contractile properties</i></p>	

<p>3.1.7 Maximal strength: peak force in N generated during a MVC. (NEW). The resting forces recorded prior to the effort are usually subtracted from the peak value⁽⁷⁸⁾.</p> <p>Specify:</p> <ul style="list-style-type: none"> - the length of hold for the MVC e.g. 10s contraction duration - how the peak score was obtained, e.g. peak during a single MVC, best of or average of 3 contractions. 	<p>Higher peak value indicates higher muscle strength.</p>
<p>3.1.8 Speed of contraction: rate of force development measured as the mean slope of the ascending curve in N/s during a fast MVC⁽⁷⁹⁾. (NEW)</p>	<p>Higher rate of force (steeper slope) is indicative of a faster generation of force.</p>
<p>3.1.9 Speed of relaxation: rate of force reduction measured as the mean slope of the descending curve in N/s during PFM relaxation⁽⁸⁶⁾. (NEW)</p>	<p>Lower values are indicative of slower relaxation.</p>
<p>3.1.10 Number of rapid contractions: see section 2.2.16 for definition and rating. A contraction must comprise an ascending and a descending phase with the amplitude of the PFM forces returning to the resting state post contraction⁽⁷⁹⁾.</p>	<p>Higher number of contractions are suggestive of higher speed of contraction but also better motor control, as the task requires alternation between MVC and complete rest.</p>
<p>3.1.11 Normalised area under the force curve: the area under the force curve divided by maximal force and multiplied by 100 (in % x prescribed s) during a sustained MVC⁽⁷⁹⁾. (NEW)</p>	<p>Higher normalised area is indicative of better muscle endurance.</p>

434 Abbreviations: N, Newtons; PFM, pelvic floor muscles; MVC, maximum voluntary contraction.

435

436 **3.2 Myotonometry:** an investigation that measures muscle tone characteristics by applying a
 437 mechanical impulse to the tissue⁽⁸⁹⁻⁹¹⁾. (**NEW**) The device elicits oscillations of muscle after a probe
 438 applies a brief mechanical impulse with quick release under constant pre-load to the skin over the
 439 muscle belly. Myotonometry has been used externally on the perineum to measure superficial PFM
 440 stiffness. It cannot be used intra-vaginally to measure levator ani function as the probe must be
 441 perpendicular to the muscle and therefore cannot be used to interpret levator ani function. Table 9
 442 describes the most frequent parameters measured with myotonometry that can be computed from
 443 the oscillation curve as well as their definitions, specifications and findings⁽⁹²⁾. It should be noted
 444 that the tissues that lie between the probe and the muscle (e.g. skin, adipose tissues, connective and
 445 fascial tissues) can also influence the measurements.

446

447 Table 9 Parameters and findings evaluated with myotonometry

Parameters, specifications (units of measure) and measurement processes	Outputs and interpretation of findings
3.2.1 Oscillation frequency: characterises the intrinsic tension of the muscle in its passive or resting state in the absence of voluntary contraction ⁽⁹³⁾ . (NEW) Measured in Hz.	A higher oscillation frequency (Hz value) indicates higher muscle tone ^(92,93) .
<i>a). Biomechanical properties:</i>	
3.2.2 Stiffness: as defined in 3.1.4 for dynamometry. However, the method of application of the force is different to that described in 3.2.2; with this device, an external sensor applies a deformation perpendicular to the tissue.	A higher N/m value indicates higher muscle stiffness.
3.2.3 Logarithmic decrement: characterises elasticity and dissipation of mechanical energy. Measured as $\ln(D)$ ($D = \ln$	Elasticity is inversely proportional to decrement, therefore, if the decrement of a muscle decreases,

<p>[a1/a3])⁽⁹³⁾. It indicates the ability of the tissue (including muscle) to recover its shape after being deformed. (NEW)</p>	<p>the muscle elasticity increases. The smaller the decrement value, the smaller will be the dissipation of mechanical energy and the higher the elasticity of a tissue.</p>
<p><i>b). Viscoelastic properties:</i></p>	
<p>3.2.4 Mechanical stress relaxation time: the time for a muscle to recover its shape from deformation after a voluntary contraction or removal of an external force. (NEW). Measured in milliseconds⁽⁹²⁾.</p>	<p>The longer the time the more relaxation has occurred in the tissue.</p>
<p>3.2.5 Creep: the gradual elongation of a tissue over time when placed under a constant tensile stress. (NEW): Measured by the the ratio of relaxation time to deformation time (Deborah number).</p>	<p>The higher the creep, the less elasticity the tissue has and the more likely is permanent stretch or deformation.</p>

448 Abbreviations: Hz, hertz; N/m, newtons/metre.

449

450 **3.3 Manometry:** an investigation that measures pressure^(27,75).

451 **3.3.1 Pelvic floor manometry:** Measurement of resting pressure or pressure rise generated
452 during contraction of the PFM using a manometer connected to a sensor, which is inserted into
453 the urethra, vagina or rectum⁽²⁷⁾ ..

454 **3.3.1.a) Intra-urethral manometry:** Manometry performed via the urethra. One example is
455 the urethral pressure profile that is undertaken as part of a urodynamic investigation⁽⁹⁴⁾.
456 **(NEW)**

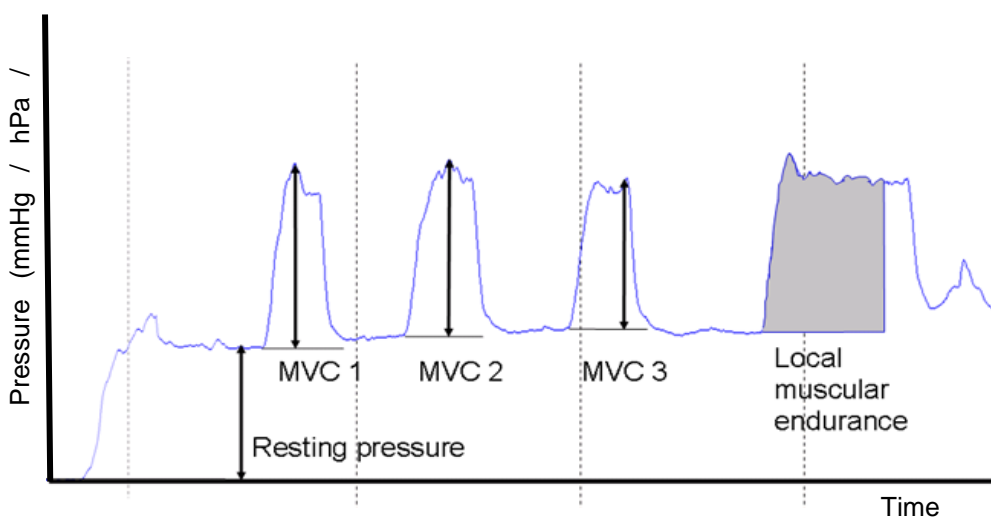
457 **3.3.1.b) Intra-vaginal manometry:** Manometry performed via the vaginal canal. **(NEW)**

458 **3.3.1.c) Intra-anal manometry:** ^{FN3.3} Manometry performed via the anal canal. **(NEW)**

459

460 Pelvic floor manometric tools traditionally have measured pressure in mmHg, hPa or cmH₂O,
461 however new and future devices may provide output using different units. It should be specified
462 whether the device is calibrated to zero / atmospheric pressure prior to insertion⁽²⁷⁾. The most
463 common parameters assessed with pelvic floor manometry (intra-vaginal and intra-anal) and
464 their findings are described in Table 10. Several common parameters are illustrated in Figure 4.

465



466

467 Figure 4: Graphical illustration of pelvic floor muscle manometry readings (modified from
468 Ingeborg Hoff Braekken).

469

470 Table 10. Parameters and findings evaluated with pelvic floor manometry

Parameters, specifications (units of measure) and measurement processes	Outputs and interpretation of findings
<i>a). Parameters assessed at rest</i>	
3.3.1.1 Resting pressure: the pressure recorded at rest in mmHg, hPa or cmH ₂ O. For greater accuracy, a mean resting pressure	Higher resting pressure may be a surrogate measure of increased PFM tone. However, the value

<p>may be calculated over a specified period to account for fluctuations^(95,96). (NEW)</p> <p>Resting pressure may be influenced by PFM tone (i.e. summative contribution of the active and passive components).</p>	<p>should be interpreted with caution as the measurement is not limited to pressure originating from the PFMs (e.g. intra-abdominal pressure, vaginal tissue scaring, rectal contents may contribute to resting pressure).</p>
<p><i>b). Parameters evaluating contractile properties</i></p>	
<p>3.3.1.2 Peak pressure during a maximum voluntary contraction: highest pressure recorded during a PFM MVC in mmHg, hPa or cmH₂O. (NEW)</p> <p>As the pressure measured does not confirm its origin, it is important to ensure the validity of intra-vaginal measurement: 1) perform vaginal palpation before using the manometer to ensure the patient is able to correctly contract her PFMs; 2) observe the cranial movement of the vaginal probe during measurement of the muscle contraction and 3) ignore contractions associated with elevated intra-abdominal pressure (e.g. Valsalva maneuver), hip muscle contraction or any movement of the pelvis^(97,98) FN3.4.</p> <p>Specify:</p> <ul style="list-style-type: none"> - the length of hold for the MVC e.g. 3s/5s/10s contraction duration - How the peak score was obtained, e.g. peak during a single MVC /best of or average of 3 contractions⁽¹⁰¹⁻¹⁰⁸⁾. 	<p>Maximal pressure is often used as a surrogate of muscle strength e.g. higher pressure being related to higher strength.</p>

<p>3.3.1.3 Time to peak pressure: time in seconds from onset of muscle contraction to maximal pressure. (NEW)</p>	<p>Shorter time to peak is indicative of a faster generation of pressure.</p>
<p>3.3.1.4 Speed of contraction: rate of pressure rise measured as the mean slope of the ascending curve in hPa/s during a fast MVC. (NEW)</p>	<p>Higher rate of force (steeper slope) is indicative of a faster generation of pressure.</p>
<p>3.3.1.5 Speed of relaxation: rate of pressure reduction measured as the mean slope of the descending curve in hPa/s during PFM relaxation. (NEW)</p>	<p>Lower values are indicative of a slower relaxation.</p>
<p>3.3.1.6 Number of rapid contractions: see 2.2.16 and 3.1.10 for definitions and ratings.</p>	<p>See 3.1.10 for interpretation.</p>
<p>3.3.1.7 Time to return to baseline pressure: time in seconds from maximal pressure to relaxation state. (NEW)</p>	<p>Longer duration suggests slower relaxation.</p>
<p>3.3.1.8 Duration of a sustained contraction: the length of time in seconds that a contraction can be sustained during MVC or at a specific % of MVC. (NEW). Specify if it is a maximal contraction or a % of MVC e.g 60%^(96,101,104,106,108) and the threshold used to indicate that the target is no longer maintained.</p>	<p>A shorter duration suggests a lower endurance. Duration of contraction could be used as an indication of endurance e.g. longer contraction being related to better endurance.</p>
<p>3.3.1.9 Area under the pressure curve during a sustained contraction: the area under the pressure curve in hPa multiplied by time in s during a sustained MVC or at a specific percentage of MVC. This represents the total work performed. (NEW). Specify the duration of the contraction e.g 10s, 30s, etc.^(95,107).</p>	<p>Higher area under the pressure curve above resting pressure reflects better muscle endurance.</p>

471 Abbreviations: PFM, pelvic floor muscles; MVC, maximum voluntary contraction.

472

473 **3.3.2 Anorectal manometry** FN3.5: is a pressure test to assess the structure and physiological
 474 function of the anorectal complex (**CHANGED**)⁽¹¹⁾. Water perfused and solid-state pressure
 475 transducers are used in combination with a balloon positioned in the anal canal⁽²⁶⁾. The most
 476 commonly used PFM parameters and findings are described in Table 11. FN3.6

477
 478 Table 11. Parameters and findings evaluated with anorectal manometry

Parameters, specifications (units of measure) and measurement processes	Outputs and interpretation of findings
<i>a). Parameters assessed at rest</i>	
<p>3.3.2.1 Functional anal length: the length (mm) of the anal canal over which resting pressure exceeds that of the rectum. (CHANGED)⁽¹¹⁾ The length of the canal is measured either by station pull-through or continuous pull-through⁽¹¹⁾.</p>	<p>Functional anal canal length has been shown to be shorter in females with fecal incontinence and longer in females with chronic constipation⁽¹⁰⁹⁾.</p>
<p>3.3.2.2 Maximum resting pressure: the highest pressure (in mmHg, hPa or cmH₂O) along the anal canal measured in the axial plane at a specific point. (CHANGED)⁽¹¹⁾</p>	<p>Internal anal sphincter (IAS) (smooth muscle) is responsible for 55-85% of the anal pressure, and is variable along the length of the anal canal with the proximal two thirds being more reliant on IAS tone to maintain adequate resting pressures. Low anal resting pressure is associated with passive fecal soiling. High anal resting pressure may be a feature of constipation⁽¹¹⁰⁾.</p>
<i>b). Parameters evaluating contractile properties</i>	

<p>3.3.2.3 Maximum pressure during MVC / maximum squeeze pressure: is the anal canal pressure (in mmHg, hPa or cmH₂O) measured during maximum voluntary contraction (MVC) in a specific location (CHANGED)⁽¹¹⁾.</p>	<p>The pressure increment above resting pressure during these maneuvers is primarily a representation of EAS function. Range of normative values varies according to the particular measurement device in a laboratory⁽¹¹⁾. Decreased voluntary anal sphincter contraction is associated with fecal incontinence especially fecal urgency⁽¹¹⁰⁾.</p>
<p>3.3.2.4 Duration of sustained contraction MVC / endurance squeeze pressure: is the length of time (in seconds) the individual is able to maintain the pressure during the MVC (CHANGED)⁽¹¹⁾.</p>	<p>Shorter duration suggests a lower endurance. To assess the endurance squeeze pressure, measurements are taken during a 5-10s squeeze. By calculating fatigability, the fatigue rate (using reduction of the mean pressure over 1-s periods throughout the endurance squeeze) can be derived⁽¹¹⁾.</p>
<p>3.3.2.5 Number of rapid contractions: see 2.2.16 and 3.1.10 for definitions and ratings.</p>	<p>See 3.1.10 for interpretation.</p>
<p>3.3.2.6 Involuntary maximum squeeze pressure: the pressure (in mmHg, hPa or cmH₂O) created involuntarily by the PFM during a maximal cough⁽¹⁰⁰⁾ (CHANGED)⁽¹¹⁾. FN3.7</p>	<ul style="list-style-type: none"> • present; numerical values of pressure change may be used to further quantify • absent; associated with faecal incontinence⁽¹¹¹⁾
<p>3.3.2.7 Balloon expulsion pressure: the anal canal pressure (in mmHg, hPa or cmH₂O) during straining with a filled balloon in the rectum⁽¹¹⁾</p>	<ul style="list-style-type: none"> • increase from resting pressure suggests paradoxical contraction (see 4.3.1) and is associated with evacuation dysfunctions • no change

	<ul style="list-style-type: none"> • decrease from resting pressure (normal)
<p>3.3.2.8 Rectoanal inhibitory reflex (RAIR): the relaxation response in the IAS following rectal distension (in mmHg, hPa or cmH₂O) ⁽¹¹⁾. It is elicited by rapid inflation to first sensation of a balloon positioned in the distal rectum during anal manometry at the level of the proximal high-pressure zone.</p>	<ul style="list-style-type: none"> • present: a drop of at least 25% of resting pressure has to occur with subsequent restoration to at least two thirds of resting pressure for the RAIR to be deemed present. This reflex is thought to underlie the sampling response that allows rectal contents to be sensed by the anal mucosa, thus ensuring continence of flatus and stool^(11,112) • absent: seen in Hirschsprung disease, fecal incontinence, constipation and after anorectal surgery⁽¹¹⁰⁾

479 Abbreviations: PFM, pelvic floor muscles; MVC, maximum voluntary contraction; IAS internal anal
480 sphincter.

481

482 **3.3.2.9 Vector manometry:** a three-dimensional pressure profile of the anal canal.
483 **(CHANGED)**⁽¹¹⁾. Measures of total anal canal pressure and symmetry are made. The vector
484 volume is the volume of the 3D shape generated and provides a value which reflects the
485 overall length and symmetry of the sphincter.

486 **3.3.2.10 High resolution manometry:** complete definition of the intra-anal pressure
487 environment using a catheter with a large number of pressure sensors spaced less than 0.5 mm
488 apart along the length of the catheter⁽¹¹⁾.

489 **3.3.2.11 Ambulatory anorectal manometry:** is a test performed using solid-state catheters
490 in ambulant subjects an over an extended period of time **(CHANGED)**⁽¹¹⁾.

491

492 **3.4 Electromyography (EMG):** is the recording of electrical potentials generated by the
493 depolarization of muscle fiber membranes⁽²⁷⁾. Investigators reporting PFM EMG studies should
494 state the position of the patient, the recording equipment⁽²⁶⁾ and conditions used as summarised in
495 Box 2. Nerve conduction studies e.g. pudendal nerve testing, are beyond the scope of this document.

496

497 Box 2: System specifications

Recommendations for reporting EMG studies (based on the recommendations of the International Society of Electrophysiology and Kinesiology⁽¹¹³⁾).

Reports on surface EMG should include:

- electrode material (e.g., Ag/AgCl)
- electrode geometry (discs, bars, rectangular)
- number and size (e.g., diameter, radius, width, length)
- interelectrode distance
- use of gel or paste
- skin/mucosal preparation (e.g. alcohol applied to cleanse skin, skin abrasion, shaving of hair, etc.)
- electrode location, orientation over muscle with respect to tendons, motor point (if known) and muscle fiber direction.
- type of ground electrode used, location.

Reports on intramuscular wire electrodes should include:

- wire material (e.g., stainless steel)
- if single- or multi-strand
- if single or bipolar wire
- interelectrode distance
- insulation material

- length of exposed tip
- method of insertion (e.g., hypodermic needle)
- depth of insertion/method of insertion guidance
- location of insertion in the muscle
- type of ground electrode used, location.

Amplifiers should be described by the following:

- type (monopolar, differential, double differential, etc.)
- pre-amplification at the level of the electrode
- input impedance
- Common Mode Rejection Ratio (CMRR)
- actual gain range used.

Filtering of the raw EMG should be specified by: FN3.8

- low and/or high pass filter properties (e.g. cut-off frequencies, order)
- filter types (e.g., Butterworth, Chebyshev, Notch, etc.)
- notch filter

498

499 Important considerations when interpreting EMG signals: Baseline and contractile sEMG amplitude
 500 is affected by properties of the electrode, configuration of electrodes, recording system and
 501 patient/individual characteristics. Raw amplitude cannot be compared between individuals because
 502 the signal's amplitude is affected by many factors (e.g. cutaneous/mucosal tissue thickness, vaginal
 503 lubrication, positioning/direction of electrodes with respect to the muscle and muscle fibres, and
 504 properties of the detection system⁽¹¹⁴⁻¹¹⁶⁾). As a consequence, normalisation of the sEMG amplitude
 505 is considered critical when comparing data across individuals⁽¹¹⁷⁾.

506 **3.4.a) Artefact:** extraneous information in the EMG signal from sources other than the target
 507 muscle, such as the environment (e.g. electromagnetic radiation) or other body functions.

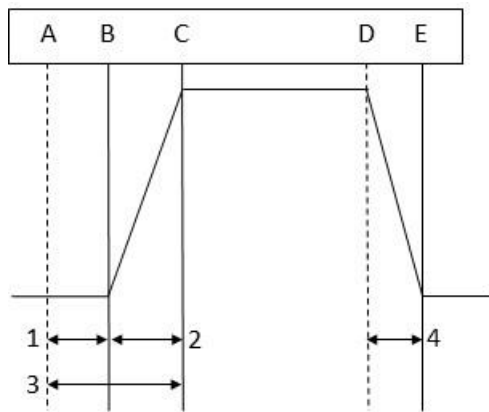
508 Artefact examples include movement or contact quality artefact, heart rate, skin electrode shear,
509 and electrode bridging **(CHANGED)**⁽²⁷⁾.

510 **3.4.b) Cross talk:** muscle activity from nearby muscles that can contribute to the recorded EMG
511 amplitude and be misinterpreted as PFM activation⁽²⁷⁾. FN3.9

512 **3.4.1 Intramuscular EMG:** is a recording of motor unit action potentials using needle
513 (concentric or monopolar) or wire electrodes inserted into muscles^(75,119). **(CHANGED)**⁽²⁷⁾. This
514 is not typically used in clinical assessment. The electrodes can be inserted to assess the
515 superficial (e.g. bulbocavernosus) and deep layers (e.g. levator ani) of the PFMs as well as the
516 urethral and anal sphincters⁽¹²⁰⁾. This assessment as a rule focuses on the motor units to
517 investigate motor unit physiology and pathophysiology. Parameters evaluated with concentric
518 needle EMG can be used to differentiate between normal, denervated, reinnervated and
519 myopathic muscle^(121,122) Quantitative EMG includes analysis such as the multi-motor unit
520 potential analysis⁽¹²²⁾ and the interference pattern analysis (turns/zero crossing or amplitude)⁽¹²²⁾.

521 **3.4.2 Surface electromyography (sEMG):** is a recording of motor unit action potentials using
522 surface electrodes placed on the skin or mucosa close to the muscle of interest. Recordings are
523 also used in assessment of the activation pattern/‘behaviour’ (sometimes referred to as
524 kinesiological electromyography) of a particular muscle during a defined activity⁽¹²¹⁾. sEMG
525 requires electrodes placed on the skin of the perineum or inside the urethra, vagina or rectum
526 **(CHANGED)**^(12,27). Parameters and findings evaluated with sEMG are described in Table 12.
527 Several common parameters are illustrated in Figure 5.

528



A = signal to contract
 B = onset of muscle activity
 C = peak muscle recruitment
 D = signal to relax
 E = return to baseline

1. Reaction time
2. Time to peak activation
3. Time from command to peak
4. Time to return to baseline muscle activity

529

530 Figure 5: Parameters measured using electromyography

531

532 Table 12. Parameters and findings evaluated with sEMG

Parameters, specifications (units of measure) and measurement processes	Outputs and interpretation of findings
<i>a). Parameters assessed at rest</i>	
<p>3.4.2.1 Baseline muscle activity: the amount of microvolts generated by activation of motor units in the target muscle during rest^(27,75). FN3.10, FN3.11</p>	<p>3.4.2.1.1 Inconsistent resting baseline: the variation of baseline between contractions, between sets, or between days^(27,75).</p> <p>3.4.2.1.2 Elevated resting activity: an increase in the active component of muscle tone; (the passive/viscoelastic component is not captured by sEMG). (NEW).</p>
<i>b). Parameters evaluating contractile properties</i>	
<p>3.4.2.2 Signal amplitude: microvolts (μV) a muscle generates⁽²⁷⁾. Specify:</p>	<p>sEMG amplitude reflects muscle activation⁽¹¹⁷⁾. Increase in sEMG amplitude is related to the recruitment of motor units and increased firing</p>

<p>- MVC contraction duration (s) - how the signal was processed. Signals are usually rectified and filtered to measure amplitude⁽¹¹⁴⁾ i.e. average rectified value or root-mean-square⁽¹¹⁴⁾.</p>	<p>rate⁽¹¹⁸⁾. The amplitude of the signal should not be interpreted as a direct force measurement because the relationship between force and EMG is generally not linear and is affected by</p>
<p>3.4.2.3 Peak amplitude: the highest sEMG amplitude achieved measured in microvolts^(27,75). Specify the duration (s). Measured during an MVC or functional activities such as postural tasks or incontinence provocative activities^(125,126). FN3.12</p>	<p>type of contraction (concentric/isometric/eccentric), speed of contraction.). During strength training, early gains in force output are mainly related to an increase in motor unit recruitment and discharge frequency which will result in a higher signal</p>
<p>3.4.2.4 Normalization of the amplitude: the value obtained during a specific task as a percent relative to the electrical activity detected during a MVC^(113,117). (NEW)</p>	<p>amplitude. Later gains explained by hypertrophy⁽²⁷⁾ are not reflected in increased sEMG amplitude</p>
<p>3.4.2.5 Time to peak muscle activation: time in ms or s from onset of muscle activity to peak activity. (NEW)</p> <p>Rate of change: the mean slope of the ascending curve in μVs during a fast MVC. (NEW)</p>	<p>3.4.2.5.1 Slow recruitment: a longer time to peak muscle activation in s or a slower rate of change⁽¹²⁷⁾ (CHANGED)⁽²⁷⁾. FN3.13, FN3.14</p>
<p>3.4.2.6 Reaction time: the latency (time in ms) between a stimulus (or the command) and the onset of muscle activation⁽¹²⁸⁾. (NEW) FN3.15</p> <p>3.4.2.7 Time from command to peak: time in ms from stimulus to peak activity. (NEW) This term</p>	<p>3.4.2.6.1 Slow reaction time: a longer time to initiate muscle activation. (NEW)</p>

<p>encompasses both the reaction time and the time to peak muscle activation.</p>	
<p>3.4.2.8 Time to return to baseline muscle activity: time in s from peak activity to resting activity. (NEW)</p> <p>Rate of change: the mean slope of the descending curve in uV/s during a fast MVC.</p>	<p>3.4.2.8.1 Slow de-recruitment: slow relaxation of the muscle contraction⁽²⁷⁾.</p>
<p>3.4.2.9 Rate of change of amplitude during sustained contraction: the change in sEMG amplitude divided by the duration of the contraction: $EMG_{final} - EMG_{initial}/time(s)$⁽¹²⁹⁾. (NEW). The contraction could be sustained or intermittent at different % of MVC⁽¹²⁹⁾.</p>	<p>A higher rate of change will be indicative of lower endurance.</p>
<p>3.4.2.10 Timing of muscle activity: onset of the activation in milliseconds can be assessed in relation to onset of activation in other muscles, provocative activities or other aspects of a task. (NEW)</p>	<ul style="list-style-type: none"> • normal • delayed: delayed activation of the PFM relative to the onset of a cough or a postural perturbation has been found in women with stress urinary incontinence⁽¹²⁶⁾
<p>3.4.2.11 Duration of a sustained contraction: the duration in seconds that a contraction could be sustained at a specific % of MVC⁽¹²⁹⁾. (NEW)</p>	<p>A shorter duration suggests lower endurance.</p>
<p>3.4.2.12 Power spectrum: the distribution of frequency components of the sEMG signals, measured in Hz⁽¹¹⁴⁾. (NEW)</p>	<p>The median frequency of the sEMG power spectrum shifts to lower frequencies as a muscle fatigues due to altered muscle fiber recruitment</p>

	and other changes in the contractile properties ^(130,131) .
--	--

533 Abbreviations: sEMG, surface electromyography; MVC, maximum voluntary contraction; PFM,
534 pelvic floor muscles; uV microvolts.

535

536 **3.5 Imaging:** refers to the process of creating images using high-energy modalities to allow
537 visualization of body tissues. Imaging provides tissue-specific evaluation to identify if
538 morphological properties (e.g. trauma or deficit) are present, which may relate to an individual's
539 presenting symptoms^(27,75). In this document, we focus on ultrasound and MRI assessment and the
540 terms related to PFM morphology and function, as well as the influence of other structures on PFM
541 support and contractility investigated using these tools. It is not within the scope of this document
542 to describe imaging of organ structures.

543 **Ultrasound imaging:** Pelvic floor ultrasound imaging measures PFM morphology and function
544 via trans-abdominal, trans-perineal, trans-vaginal and trans-anal placement of the transducer
545 **(CHANGED)**.^(12,43) This investigation applies diagnostic techniques taken in B-mode that use
546 high-frequency sound waves to image internal structures. The image is formed by the differing
547 reflection signals produced when a beam of sound waves is projected into the body and bounces
548 back at interfaces between those structures. Ultrasound evaluation may be undertaken as:

549 **3.5.1.a)** Two-dimensional (2D) ultrasound: the transducer sends and receives ultrasound
550 waves in one anatomical plane. The reflected waves are used to generate grey scale images
551 of structures in the field of view in this anatomical plane.

552 **3.5.1.b)** Three-dimensional (3D) ultrasound: creates volume data from multiple 2D images
553 which are gathered by reflected waves at a variety of angles. Software integrates this
554 information to create a single static 3D image.

555 **3.5.1.c) Four-dimensional (4D) ultrasound:** is similar to 3D US, but the image is repeated at
556 intervals over time. This technique requires the use of a 3D/4D transducer and enables real-
557 time visualization of 3D images.

558 **3.5.1.d) Tomographic ultrasound:** is viewing US imaging in sections. It allows the depiction
559 of arbitrarily defined planes from volume data obtained in 3D or 4D US^(132,133).

560 Measurements are best understood by referring to anatomical planes of the body, i.e coronal
561 (frontal), sagittal and axial (horizontal or transverse) planes.

562

563 **3.5.1.1 Trans-abdominal pelvic floor ultrasound:** A 2D imaging technique to scan pelvic
564 floor structures, using a convex transducer is placed in the supra-pubic region. **(NEW)** It can
565 be oriented longitudinally to measure bladder base displacement in the mid-sagittal or
566 parasagittal plane or oriented transversely to measure bladder base symmetry and
567 displacement in the transverse plane. Trans-abdominal pelvic floor ultrasound is primarily
568 used in clinical settings rather than for research purposes due to limitations measuring the
569 image (no bony landmarks in view and difficulties for operator to keep transducer in plane -
570 operator error is high). Artefact in measurement may also occur with incorrect PFM
571 contraction when abdominal muscle contraction occurs (which pushes the transducer
572 ventrally) and varying levels of bladder fullness (adherence to a fluid intake protocol may
573 mitigate this limitation). Poor agreement between transverse and sagittal findings suggests
574 measurement in the two planes evaluate displacement at different locations during a PFM
575 contraction⁽¹³⁴⁾.⁽¹³⁴⁾. Table 13 describes the parameters and anatomical landmarks evaluated
576 in the mid-sagittal plane, during different activity states of the PFM: rest, contraction and
577 bearing down.

578

579 Table 13. Parameters and findings evaluated with trans-abdominal ultrasound imaging in the mid-
 580 sagittal plane

Parameters, specifications (units of measure) and measurement processes	Outputs and interpretation of findings
<p>3.5.1.1.1 Bladder base displacement FN3.16: a marker is placed at the point of greatest displacement (mm or cm) of the infero-posterior bladder wall at rest and at maximal contraction or bearing down⁽¹³⁵⁾. Direction and displacement of the bladder base movement from rest to final position. (NEW). The bladder base is the most infero-posterior aspect of the bladder wall.</p>	<p><i>PFM contraction:</i> Displacement from rest of the bladder base during (attempted) PFM contraction⁽¹³⁶⁾:</p> <ul style="list-style-type: none"> • Elevation (normal response): movement of the bladder base in a cephalad and ventral direction toward the pubic bone infers contraction of the levator ani/puborectalis • No change • Descent: movement of the bladder base caudal and posterior away from the pubic bone infers elevated intra-abdominal pressure – PFMs may be active but this cannot be confirmed. <p><i>Bearing down:</i> Displacement of the bladder base during sustained increased intra-abdominal pressure:</p> <ul style="list-style-type: none"> • Elevation • No change • Descent

581 Abbreviations: PFM, pelvic floor muscles.

582

583 Parameters and findings evaluated with trans-abdominal imaging in the transverse plane –
 584 during different activity states of the PFM (rest, contraction and bearing down) – are described
 585 in Table 14.

586

587 Table 14. Parameters and findings evaluated with trans-abdominal ultrasound imaging in the transverse
 588 plane

Parameters, specifications (units of measure) and measurement processes	Outputs and interpretation of findings
<p>3.5.1.1.2 Symmetry of the bladder base: equal curvature of bladder base with probe placed in the transverse plane. (NEW)</p>	<p><i>Rest:</i> Symmetrical or asymmetrical. Asymmetry can be related to unilateral increased tone, unilateral decreased tone, operator error in probe position, or asymmetry of passive support (e.g. unilateral ligament damage/trauma). FN3.17</p>
<p>3.5.1.1.3 Bladder base displacement FN3.18: see 3.5.1.1.1. Movement of the bladder base (in mm or cm) is used as a surrogate measure for activity of the PFM.</p>	<p><i>PFM contraction:</i> Displacement of the bladder base during attempted PFM contraction:</p> <ul style="list-style-type: none"> • Elevation (normal response): movement of the bladder base in a cephalad/ventral direction No change • Descent: movement of the bladder base in a caudal/dorsal direction <p><i>Bearing down:</i> Displacement of the bladder base during sustained increased intra-abdominal pressure:</p> <ul style="list-style-type: none"> • Elevation • No change • Descent (normal response)

589 Abbreviations: PFM, pelvic floor muscles.

590

591 **3.5.1.2 Introital pelvic floor ultrasound:** 2D/3D/4D imaging technique to scan pelvic floor
 592 structures using an endocavity^{3.19} transducer placed against the vaginal introitus/vulva or
 593 perineum⁽⁴⁾. **(NEW)** The transducer may be oriented ventrally/anteriorly to assess the pelvic

594 floor structures (prolapse, levator ani muscle anatomy and function, and periurethral area), or
 595 oriented posteriorly to assess the anal sphincter structures.

596 **3.5.1.3 Perineal pelvic floor ultrasound:** 2D/3D/4D imaging technique to scan pelvic floor
 597 structures using a convex transducer placed against the perineum/vulva⁽⁴⁾. **(NEW)** The
 598 transducer may be oriented longitudinally/sagittally (for bladder neck/urethra, prolapse, and
 599 levator ani muscle assessment), or oriented transversely (for assessment of anal canal,
 600 sphincters). The terms transperineal and translabial ultrasound are both used to refer to
 601 perineal ultrasound.

602
 603 Parameters and findings evaluated with perineal and introital pelvic floor ultrasound – during
 604 different activity states of the PFM or actions (rest, contraction and bearing down) – are
 605 presented in Table 15.

606
 607 Table 15. Parameters and findings evaluated with perineal and introital ultrasound imaging assessed
 608 in the mid-sagittal plane using a 2D/4D transducer oriented longitudinally/sagittally.

Parameters, specifications (units of measure) and measurement processes	Outputs and interpretation of findings
<i>a) Parameters and anatomical landmarks assessed in the mid-sagittal plane using a 2D/4D transducer oriented longitudinally (f)</i>	
<p>Bladder neck parameters: measurement of bladder neck position</p> <p>3.5.1.3.1 Bladder neck position: refers to the bladder neck position relative to the pubic symphysis (PS)⁽¹³⁷⁾. The position is analyzed in a horizontal (x-axis) and vertical position (y-axis)</p>	<p><i>Rest:</i> Quantification of bladder neck position at rest from the horizontal and vertical distances from the PS^(138,145) Resting position of the bladder neck was</p>

relative to a horizontal reference line (measured in mm or cm).

(NEW)

Specify if using:

the infero-posterior margin (Figure 6)⁽¹³⁸⁾ FN3.20, the lowest margin⁽¹³⁹⁾, or the central axis (line drawn from the anterior to the posterior margin) of the PS (Figure 7)⁽¹⁴⁰⁾;

the middle of the proximal urethra for the internal meatus⁽¹⁴¹⁾, the anterior bladder neck⁽¹⁴²⁾ or equidistant points along the urethra from bladder neck to external urethral meatus⁽¹⁴³⁾.

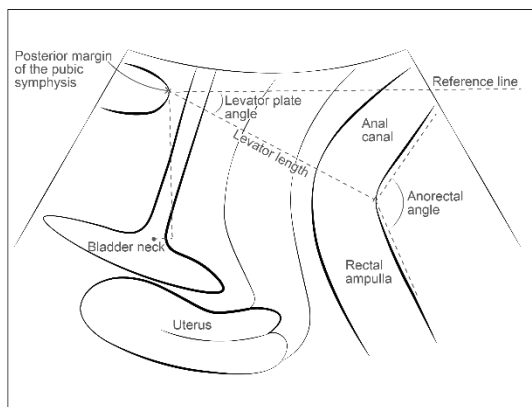


Figure 6: Perineal ultrasound parameters and anatomical landmarks assessed in the mid-sagittal plane using a horizontal reference line drawn from infero-posterior margin of the pubic symphysis.

found to be higher after PFM training⁽¹⁴³⁾.

PFM contraction: Cranio-ventral displacement of the bladder neck⁽¹⁸⁾ measured as: a decrease in x-value and increase in y-value. The ventro-cranial displacement of the bladder neck is measured as displacement = $\sqrt{(\Delta x^2 + \Delta y^2)}$ ^(141,145). The higher the value, the greater the ventro-cranial displacement of the bladder neck (bladder neck lift), which reflects the lifting action of the PFM^(141,146-148).

Bearing down: On bearing down with the instruction to relax the PFM, the dorso-caudal displacement is measured at the point of maximal displacement during the manoeuvre⁽¹⁴⁵⁾. As the proximal urethra descends, the x-value increases and the y-value decreases. The higher the value,

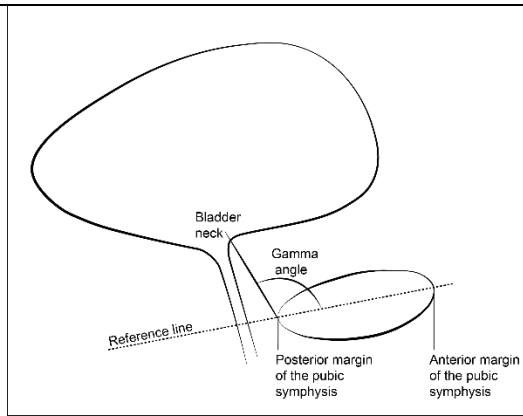


Figure 7: Perineal ultrasound parameter (gamma angle) assessed in the mid-sagittal plane using a reference line drawn from the anterior to the posterior margin of the pubic symphysis⁽¹⁴⁴⁾.

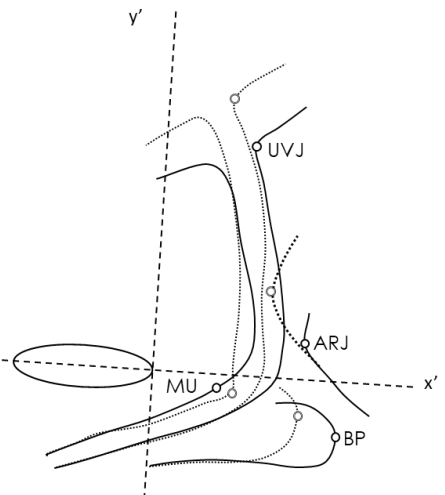
the greater the dorso-caudal displacement of the bladder neck (bladder neck descent or mobility)^(18,141,148). Higher mobility is observed in incontinent women.

3.5.1.3.2 Angle γ (Gamma)/Pubo-urethral angle: is the angle (in degrees) between the bladder neck and a line drawn from the anterior to the posterior margin of the pubic symphysis⁽¹⁴⁴⁾ **(NEW)** (see Figure 7).

Rest: Quantification of the angle at rest⁽¹⁴⁹⁾.
PFM contraction: a change of the angle γ from rest to a maximal PFM contraction. A reduction of the angle is expected as the bladder neck displaces ventrally and caudally.
Bearing down: method to assess bladder neck descent/mobility⁽¹⁴⁴⁾. A larger angle indicates a greater descent of the bladder neck⁽¹³⁸⁾, which has been related to incontinence.

<p>3.5.1.3.3 Perineal body: should appear as a triangular shaped, slightly hyperechoic (white) structure anterior to the anal sphincter⁽¹¹⁾.</p>	<p>Indicates if the integrity of the perineal body is normal or compromised.</p>
<p>3.5.1.3.4 Levator plate angle: the angle (in degrees) between a horizontal reference line at the level of the infero-posterior margin of the PS intersecting a line from the infero-posterior margin of the PS to the anorectal angle^(145,150). (NEW) (see Figure 6)</p>	<p><i>Rest:</i> Quantification of the levator angle at rest. Elevated levator plate angle may be indicative of increased tone in the PFM⁽¹⁴⁷⁾.</p> <p><i>PFM contraction:</i> An increase of the levator plate angle in comparison to the angle at rest. Levator plate excursion is calculated by subtracting the angle at rest from the angle during contraction⁽¹⁴⁷⁾.</p> <p><i>Bearing down:</i> A decrease of the levator plate angle in comparison to the angle at rest. Levator plate excursion is measured as per contraction, smaller angle is expected⁽¹⁴⁵⁾.</p>
<p>3.5.1.3.5 Levator hiatus length: the distance (mm or cm) between the infero-posterior margin of the pubic symphysis to the anorectal angle, representing the levator hiatus antero-</p>	<p><i>Rest:</i> Quantification of the levator hiatus? at rest. Smaller levator plate length could be</p>

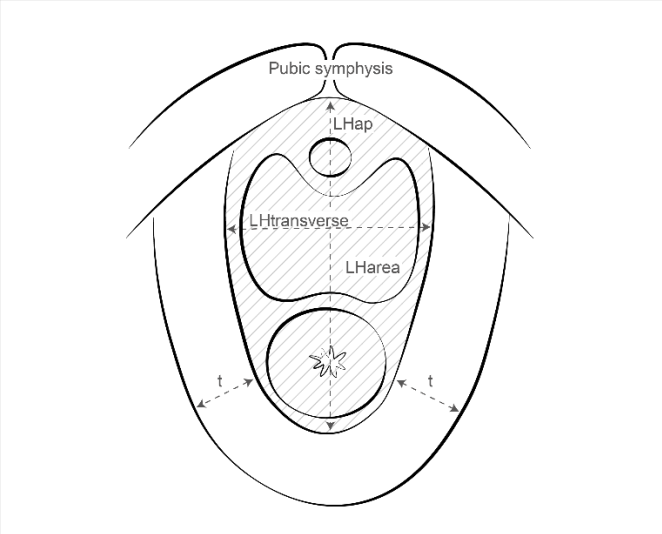
<p>posterior diameter in the mid-sagittal view^(146,150). (NEW) (see Figure 6)</p>	<p>suggestive of high tone in PFM⁽¹⁴⁷⁾.</p> <p><i>PFM contraction:</i> A reduction of the levator hiatus It has been demonstrated to reflect a PFM contraction^(137,149).</p> <p><i>Bearing down:</i> An increase of the levator plate length is expected.</p>
<p>3.5.1.3.6 Anorectal angle: the angle (in degrees), formed by the longitudinal axis of the anal canal and the posterior rectal wall⁽¹¹⁾.</p>	<p><i>Rest:</i> Quantification of the anorectal angle at rest. Smaller anorectal angle could be suggestive of increased tone in the PFM⁽¹⁴⁷⁾.</p> <p><i>PFM Contraction:</i> A reduction in the anorectal angle during a PFM contraction. The excursion of the anorectal angle is calculated as the angle during contraction of the levator ani muscle minus the angle at rest. Larger excursion could be suggestive of stronger activation of the PFM^(147,151,152).</p>

	<p><i>Bearing down:</i> Widening of the anorectal angle is expected⁽¹⁵²⁾. If absent, PFM dyssynergia may be present.</p>
<p><i>b). Parameters and anatomical landmarks assessed in the mid-sagittal plane using a 2D transducer oriented longitudinally/sagittally (m)</i></p>	
<p>Displacement or position (in mm or cm) of anatomical landmarks are assessed to interpret activation of individual PFM^(28,30).</p> <p>3.5.1.3.7 Urethro-vesical junction: The point of maximal inflection of a line drawn along the dorsal border of the urethra and the bladder neck^(28,30). (NEW)</p> <p>3.5.1.3.8 Anorectal junction: The ventral-most point of a line drawn along the ventral aspect of the rectum at the anorectal junction. (NEW)</p>  <p>UVJ – Urethrovesical junction ARJ – Ano-rectal junction MU – Mid-urethra BP – Bulb of the penis</p>	<p>For the displacement of the anatomical landmarks described below, the displacement during contraction and cough are measured in relation to the resting position values^(28,154). Movement of these landmarks has been correlated with activation of levator ani (puborectalis)⁽²⁸⁾</p> <p>For 3.5.1.3.7 and 3.5.1.3.8: <i>Rest:</i> The position of these landmarks in the caudo-cranial and antero-posterior planes can be quantified relative to the dorsal pole of the PS at rest (see Figure 8). Lower resting position has been observed in incontinent men⁽¹⁵⁴⁾.</p>

<p>Figure 8: Parameters and anatomical landmarks assessed in the mid-sagittal plane using a 2D transducer oriented longitudinally/sagittally in men (reproduced with permission from Stafford et al⁽¹⁵³⁾).</p> <p>Legend:</p> <p>This figure overlays two images illustrating the anatomy at rest (continuous lines) and during maximal pelvic floor contraction (dotted-lines).</p>	<p><i>PFM contraction:</i> Cranio-ventral displacement is expected^(28,155).</p> <p><i>Cough:</i> Caudal-dorsal motion can be observed during the pressurization phase of cough due to levator ani muscle lengthening (probable eccentric contraction, but this cannot be confirmed from US imaging) during the phase when intra-abdominal pressure increases. This is followed by cranial-ventral displacement that occurs due to PFM shortening (concentric contraction).</p>
<p>3.5.1.3.9 Bulb of the penis: the dorsal-most point on a line drawn around the bulb of the corpus cavernosum penis. (NEW)</p>	<p><i>Contraction:</i> Cranio-ventral displacement is expected due to bulbocavernosus shortening^(28,30,154).</p> <p><i>Cough:</i> Cranio-ventral displacement is expected due to bulbocavernosus shortening⁽³⁰⁾.</p>

<p>3.5.1.3.10 Mid-urethra: A point on the ventral border of the membranous urethra that undergoes the greatest dorsal movement during contraction. This point is located within 2.5 mm either side of a line drawn between the dorsal pole of the pubic symphysis and the most dorsal aspect of the bulb of the penis (NEW) (see Figure 8).</p>	<p><i>PFM contraction:</i> Dorsal displacement is expected due to striated urethral sphincter shortening^(28,30).</p> <p><i>Cough:</i> Dorsal displacement of the mid-urethra due to striated urethral sphincter shortening^(28,30).</p>
<p><i>c). Parameters and anatomical landmarks assessed in the axial plane using the 4D transducer oriented longitudinally (f)</i></p>	
<p>3.5.1.3.11 Hiatal dimensions: cross-sectional area of the pelvic floor/levator hiatus, including antero-posterior and transverse distances⁽²⁷⁾ Measured in the plane of minimal hiatal dimensions⁽¹⁸⁾. A transverse view is obtained and the plane of minimal hiatal dimensions is identified by moving the field of view cranially and caudally until the distance between the hyperechogenic posterior aspect of the PS and the hyperechogenic anterior border of the pubovisceral muscle is at a minimum⁽¹⁵⁶⁾.</p>	
<p>3.5.1.3.11.1 Levator hiatus antero-posterior diameter: the distance (in mm or cm) delineated from the PS (anteriorly) to the edge of the of the puborectalis muscle (posteriorly). (NEW)</p> <p>3.5.1.3.11.2 Levator hiatus left-right / latero-lateral / transverse diameter: latero-lateral diameter of the levator hiatus (in mm or cm) in the plane of minimal hiatal dimensions. (NEW) The diameter from right to left is measured at the widest part, and perpendicular to the antero-posterior diameter^(11,148).</p>	<p>Findings below apply to all measurements of hiatal dimensions.</p> <p><i>Rest:</i> Quantification of the levator hiatus diameters/area at rest. Smaller diameter/area has been observed in women with pelvic pain and is may suggest increased tone in the PFM⁽¹⁴⁷⁾.</p>

<p>3.5.1.3.11.3 Levator hiatus area: defined and measured as the area (in mm² or cm²) bordered by the pubovisceral muscle, PS and inferior pubic ramus in the plane of minimal hiatal dimensions⁽¹⁴⁸⁾. (NEW)</p>	<p>Conversely, a larger hiatus has been observed in women with pelvic organ prolapse.</p> <p><i>PFM contraction:</i> A reduction of the area/diameter is expected during a maximal PFM contraction. Hiatus reductions during contraction can be calculated as the percentage of change from baseline (i.e., levator hiatus narrowing = (levator hiatus at rest – levator hiatus at contraction)/levator hiatus at rest x100)⁽¹⁴⁷⁾.</p> <p><i>Bearing down:</i> An increase in the levator hiatus diameter/area is expected on bearing down with the instruction to relax the PFM⁽¹⁵⁶⁾. The difference (or percentage of change) between the diameter at rest and on bearing down determines the degree of hiatal distension⁽¹¹⁾. Higher distension has been</p>
---	--

	observed in women with pelvic organ prolapse ⁽¹⁵⁷⁾ .
<p>3.5.1.3.12 Maximal levator ani muscle thickness: is the maximum diameter of the levator ani muscle measured in two locations bilaterally (in mm or cm). (NEW) (see Figure 9). This is usually located 1 – 1.5 cm above the minimal levator hiatus dimension. Measured perpendicular to the presumed levator ani fibre direction^(148,156).</p> <p>3.5.1.3.13 Levator ani muscle cross-sectional area: is the area (in mm² or cm²) delineated by tracing the outline of the levator ani muscle at the level of maximal muscle thickness (NEW)</p>	<p>Provides morphologic measurements of the muscle diameter and area at rest⁽¹⁵⁶⁾.</p> <p><i>Rest:</i> increased thickness has been observed after PFM training⁽¹⁵⁸⁾. Increased thickness may be indirectly related to strength⁽¹⁵⁸⁾.</p>
 <p>Figure 9: Levator hiatus dimensions measured using perineal ultrasound.</p> <p>Figure legend:</p> <p>LHarea: levator hiatus area</p> <p>LHtransverse: levator hiatus transverse diameter</p>	

<p>LHap: levator hiatus antero-posterior diameter</p> <p>t: pubovisceral thickness</p>	
<p>3.5.1.3.14 Integrity of the anterior/medial fibers of the levator ani: To assess if a disruption or disconnection of the insertion is present, direct the patient to perform a PFM contraction, and identify the plane of minimal hiatal dimensions at maximal PFM contraction. Use this plane for tomographic ultrasound imaging of the puborectalis component of the levator ani, with an interslice interval of 2.5 mm⁽⁴⁾. (NEW)</p>	<p>3.5.1.3.14.1 Complete avulsion FN3.21 is diagnosed when the 3 central slices show a loss of integrity or defect in the anterior/medial fibre of the levator ani muscle on the inferior pubic ramus resulting in a levator-urethra gap⁽⁴⁾ (NEW). A gap of more than 2.5 cm has been suggested as an indicator of avulsion⁽¹⁵⁹⁾.</p> <p>3.5.1.3.14.2 Partial avulsion: is diagnosed when at one or two of the 3 central slices show a loss of integrity/defect of the medial fiber of the levator ani muscle (CHANGED)⁽²⁷⁾.</p>
<p>3.5.1.3.15 Urethral sphincter volume: ultrasound imaging of the urethral sphincter (morphometry of the rhabdosphincter)⁽¹⁸⁾. (NEW) The internal sphincter volume (in mm³ or cm³) including the longitudinal smooth muscle and the lumen is seen as a hypoechoic (black) core whereas the external sphincter volume</p>	<p>Smaller sphincter volume is related to urinary incontinence severity⁽¹⁶³⁾ and urethral pressure⁽¹⁶²⁾. PFM training</p>

<p>or the circular striated muscle of the rhabdosphincter is seen as a hyperechoic (white) ellipsoid structure⁽¹⁶⁰⁻¹⁶²⁾.</p>	<p>results in increased sphincter volume⁽¹⁶⁴⁾.</p>
---	---

d). Parameters and anatomical landmarks assessed with tomographic ultrasound imaging plane using the 4D transducer oriented transversely

3.5.1.3.16 Integrity of the anal sphincter complex: assessment of the internal and external anal sphincter to identify presence/absence of a defect (measured in degrees). **(NEW)**. Using tomographic ultrasound imaging, the anal canal is visualised in the mid-sagittal plane and a set of 8 transverse slices is placed to encompass the entire external anal sphincter by locating one slice cranial to the external anal sphincter (at level of puborectalis, Slice 1) and another caudal to the internal anal sphincter (at level of subcutaneous part of external anal sphincter, Slice 8), leaving six slices to delineate the entire muscle (Slices 2–7) (see Figure 10). Interslice interval is varied depending on external anal sphincter dimensions^(165,166).

PFM contraction: A ‘significant’ defect is diagnosed if four out of these six slices show a defect in $>30^\circ$ of the circumference of the external anal sphincter^(4,166).

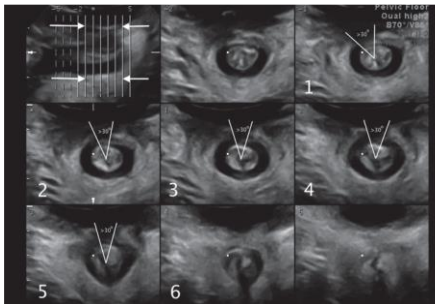


Figure 10: Assessment of the integrity of the anal sphincter complex assessed with tomographic ultrasound imaging plane (reproduced with permission from Guzman Rojas et al.⁽¹⁶⁵⁾).

609 Abbreviations: *f*, females; *m*, males; *PS*, pubic symphysis; PFM, pelvic floor muscles; MVC,
 610 maximum voluntary contraction.

611

612 **3.5.1.4 Endovaginal pelvic floor ultrasound:** an endocavity transducer is inserted into the
 613 vagina (rotational mechanical probe or radial electronic probe)⁽⁴⁾ to assess pelvic floor
 614 morphology. **(NEW)** It can be used to evaluate bladder neck/urethra, levator ani muscle, anal
 615 canal, and sphincters during different activity states of the PFM (rest, contraction and bearing
 616 down), as described in Table 16 below.

617

618 Table 16. Parameters and findings evaluated with endovaginal ultrasound imaging

Parameters, specifications (units of measure) and measurement processes	Outputs and interpretation of findings
<i>a). Parameters and anatomical landmarks assessed in the sagittal plane (2D)</i>	
3.5.1.4.1 Levator plate position: the distance (in mm or cm) between the levator plate and endovaginal probe ⁽¹⁶⁷⁾ . (NEW)	<i>Rest:</i> Quantification of the distance between the levator plate and the probe with the PFM at rest. <i>PFM contraction:</i> A reduction of the distance between the levator plate and the probe is expected during a maximal PFM contraction; may be called levator plate lift. A greater levator plate lift ratio (lift/rest x 100) detected by dynamic endovaginal sonography has been associated with higher PFM strength as determined by the Modified Oxford Scale ⁽¹⁶⁷⁾ .

<p>3.5.1.4.2 Perineal body: see 3.5.1.3.3. The depth (antero-posterior diameter) and height (supero-inferior diameter) of the perineal body can be measured in mm or cm in this plane^(11,168).</p>	<p><i>Rest:</i> Visibility of the structure and biometric measurements are identified at rest; indicate if the perineal body is visible or not visible⁽¹⁶⁸⁾.</p>
<p>3.5.1.4.3 Anorectal angle: see 3.5.1.3.6.</p>	<p><i>Rest:</i> Quantification of the anorectal angle at rest⁽¹⁶⁹⁾.</p>
<p><i>b). Parameters and anatomical landmarks assessed in the axial plane (3D)</i></p>	
<p>3.5.1.4.4 Hiatal dimensions: measurements of the following parameters are taken in the place of minimal hiatal dimension⁽⁵⁹⁾, as described in Table 17.</p> <p>3.5.1.4.4.1: Hiatal antero-posterior diameter: antero-posterior diameter (in mm or cm) of the levator hiatus measured at the level of minimum dimension (NEW)</p> <p>3.5.1.4.4.2 Hiatal transverse diameter: the diameter (in mm or cm) from right to left is measured at the widest part, and perpendicular to antero-posterior diameter (NEW)</p> <p>3.5.1.4.4.3 Hiatal area: defined and measured as the area (in mm² or cm²) bordered by the pubovisceral muscle, PS and inferior pubic ramus in the plane of minimal hiatal dimensions. (NEW)</p>	<p><i>Rest:</i> Quantification of the levator hiatus diameters/area at rest⁽⁵⁹⁾.</p>
<p>3.5.1.4.5 Levator ani thickness : defined as the diameter of the levator ani muscle (in mm or cm) at</p>	<p><i>Rest:</i> Provides morphologic measurements of the levator ani diameter.</p>

<p>the ‘9 o'clock’ and ‘3 o'clock’ positions⁽⁵⁹⁾ as described in Table 15. (NEW)</p>	
<p>3.5.1.4.6 Levator plate angle: the angle (in degrees) between the reference line and the plane of minimal levator hiatal dimensions / anorectal angle, identified via a multiplanar view⁽¹⁶⁹⁾. (NEW)</p>	<p><i>Rest:</i> This angle quantifies the levator plate position in reference to the pubic bone and the perineal body⁽¹⁶⁹⁾.</p>
<p>3.5.1.4.7 Levator ani deficiency: assessed from a 3D volume. Individual levator ani muscles are evaluated in their specific axial plane where the full length of muscle can be visualised^(170,171). (NEW)</p>	<p><i>Rest:</i> The muscles on each side for each subgroup are scored based on thickness and detachment from the pubic bone:</p> <ul style="list-style-type: none"> • 0 = no defect • 1 = minimal defect with <50 % muscle loss • 2 = major defect with >50 % muscle loss • 3 = total absence of the muscle <p>Significant levator ani deficiency is defined as a total score within the range of 12–18^(170,171).</p>
<p>3.5.1.4.8 Perineal body: this anatomical structure is visualized as an ovoid-shaped, mixed echogenicity structure. The width (latero-lateral diameter) (in mm or cm) of the perineal body can be measured in the axial plane⁽¹⁶⁸⁾.</p>	<p>as per 3.5.1.3.3</p>

619 Abbreviations: PFM, pelvic floor muscles; *PS*, pubic symphysis

620

621 **3.5.1.5 Endoanal ultrasound (EAUS):** An endocavity transducer is inserted into the anus
622 (linear array 3600 3D transducer or radial array 3600 3D transducer)⁽⁴⁾. **(NEW)** It can be used

623 to assess the external anal sphincter (EAS) and internal anal sphincter (IAS). Parameters and
 624 findings evaluated with endoanal ultrasound imaging – during different activity states of the
 625 PFM (rest, contraction and bearing down) – are described in Table 17.

626

627 Table 17. Parameters and findings evaluated with endoanal ultrasound imaging

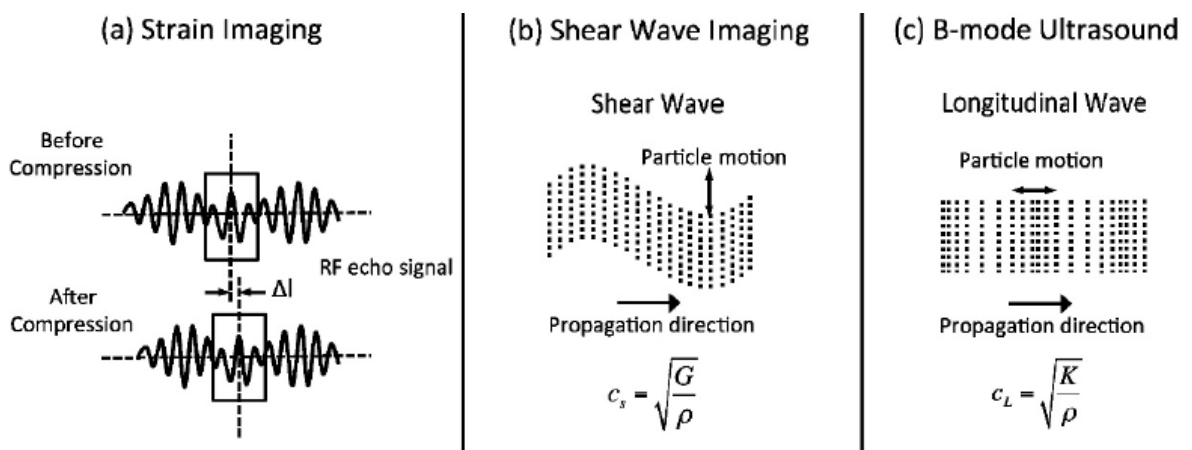
Parameters, specifications (units of measure) and measurement processes	Outputs and interpretation of findings
<p>3.5.1.5.1 Anal sphincter defect (or pathology): assessment of the internal and external anal sphincters to identify presence/absence of a defect; observed in cross-sectional images of the anal sphincter. (NEW) This measure is obtained by a probe inserted into the anal canal to a depth of approximately 6 cm and gently withdrawn down the anal canal. The anal canal is divided into three levels of assessment in the axial plane referring to the following anatomical structures^(11,172,173):</p> <ul style="list-style-type: none"> <i>i.</i> Proximal or lower level: corresponds to the subcutaneous part of the external anal sphincter where the internal anal sphincter is absent; <i>ii.</i> Middle level: corresponds to the superficial part of the EAS (concentric band of mixed echogenicity), the conjoined longitudinal layer, the IAS (concentric hypoechoic ring), and the transverse superficial perineal muscles; <i>iii.</i> Distal or upper level: the hyperechoic sling of the puborectal muscle and the complete ring of the internal anal sphincter are visualised⁽¹¹⁾. <p>The probe should be rotated so that the anterior aspect of the anal canal is superior (12 o'clock) and left lateral is oriented right (3 o'clock) on the screen. The acquisition of a three-dimensional data volume (3D ultrasound) of the anal sphincter is also possible.</p>	<p>Indicate if defect is present or absent.</p>

628 Abbreviations: EAS, external anal sphincter; IAS, internal anal sphincter.

629

630 **3.5.1.6 Ultrasound elastography:** a non-invasive imaging technique that allows
631 quantification of mechanical and elastic tissue properties following application of physical
632 stress⁽¹⁷⁴⁾. (NEW). Elastography imaging uses either compression/strain elastography or
633 shear-wave elastography^(155,175-179). The primary differences between elastography techniques
634 relate to the type or source of applied stress, and the methods of detecting displacement of the
635 examined structures. Comparison between the elastography types and B-mode ultrasound is
636 shown in Figure 11.

637



638

639 Figure 11: Ultrasound elastography physics, measurement methods (reproduced with
640 permission from Sigrist 2017 et al⁽¹⁷⁴⁾). In strain imaging (a), tissue displacement is measured
641 by correlation of RF echo signals between search windows (boxes) in the states before and
642 after compression. In shear wave imaging (b), particle motion is perpendicular to the direction
643 of wave propagation, with shear wave speed c_s related to shear modulus G . In B-mode
644 ultrasound (c), particle motion is parallel to the direction of wave propagation, with
645 longitudinal wave speed c_L related to bulk modulus K .

646 Parameters and findings evaluated with ultrasound elastography imaging are described in Table 18.

648 Table 18. Parameters and findings evaluated with ultrasound elastography imaging

Parameters, specifications (units of measure) and measurement processes	Outputs and interpretation of findings
<p>3.5.1.6.1 Shear wave elastography (SWE): Ultrasound elastography using shear waves generated by the US beam. (NEW). Different types are point SWE, 2D SWE, and transient elastography. 2D SWE uses an acoustic radiation force pulse sequence to generate shear waves, which propagate perpendicular to the ultrasound beam, causing transient displacements. The distribution of shear wave velocities at each pixel is directly related to the shear modulus in kilopascal (kPa), an absolute measure of the tissue's elastic properties. This technique is considered more objective than strain elastography⁽¹⁸⁰⁾.</p>	<p>Higher values indicate stiffer tissue, as shear waves propagate faster in stiffer tissues. Stiffness measures include both active (muscle contraction) and passive (viscoelastic properties) components of the tissue.</p>
<p>3.5.1.6.1.1 Perineal shear wave elastography: Shear wave elastography applied per perineum. (NEW). Only 2D SWE has been applied to the PFM^(155,175,179). A linear transducer is placed against the perineum/vulva. Orientation is longitudinal (for assessing urethral sphincter), or aligned with the muscle fibers for specific PFM (e.g. puborectalis) assessment. A linear or curved transducer can be used. Stiffness is evaluated using quantitative shear modulus maps represented in a color-coded elastogram displaying shear-wave velocities in</p>	<p>Higher values indicate stiffer tissue. Measures may provide evidence of stiffer tissue at rest (e.g. high activation of PFM at rest) and should increase with contraction^(155,175,179). Quality of measurement depends on orientation of the transducer (parallel with muscle fibres), accuracy of movement of the transducer to follow the movement of the muscle during contraction.</p>

<p>meters per second or tissue elasticity (shear elastic modulus) in kilopascals⁽¹⁸¹⁾.</p>	<p>Measures are compromised if there are areas in the image where the measure is saturated (stiffness greater than the measurable scale) or unable to be quantified by the system.</p>
<p>3.5.1.6.2 Strain elastography: Ultrasound elastography which measures strain in one tissue area proportional to another. (NEW). Maps, or elastograms, are developed based on the relative differences in stiffness between the area of interest and the reference tissue. The assessor applies slight and constant vertical compression through the transducer along the major axis of the tissue. Elasticity is measured by means of the Young's modulus and is defined as the ratio between the pressure measured and the strain (deformation compared to the initial length) produced⁽¹⁸²⁾. Soft tissue is more compressible than harder tissue and therefore has a higher strain (displacement) for the same applied stress (force). The results of strain elastography can only be expressed qualitatively or semi-quantitatively^(180,182).</p>	<ul style="list-style-type: none"> • Qualitative analysis: The different colors express different degrees of elasticity, usually varying from red (soft tissue) to blue (hard tissue) with intermediate colours representing intermediate degrees of stiffness⁽¹⁸²⁾. • Semi-quantitative analysis: the target tissue is selected and labeled as the region of interest (ROI) A, and the reference tissue is labeled as ROI B. Elasticity of tissue expressed as a strain ratio: B/A. The higher the value of B/A, the stiffer the target tissue.
<p>3.5.1.6.2.1 Pelvic floor strain elastography: strain elastography to assess deep PFM elasticity^(176,177) and periurethral elasticity as an estimate of urethral mobility⁽¹⁸³⁾. (NEW)</p>	<p>The higher the value of B/A, the stiffer the target tissue. A 4-point elasticity score has been used to represent levator ani muscle elasticity^(176,177).</p>

<ul style="list-style-type: none"> • To assess deep PFM: A perineal transducer is placed perpendicular to the skin in the sagittal plane to identify levator ani muscle. The levator ani muscle is selected on screen and labeled as the target tissue (region of interest [ROI] A), and the adjacent anal canal is selected and labeled as reference tissue (ROI B)⁽¹⁷⁶⁾. • To assess urethral support tissues: an endovaginal transducer is placed parallel to the urethral meatus. The target tissue is the tissue between the urethra and the vagina (para-urethral tissue) (ROI A), and the reference tissue is set at the level of the posterior tissue of the bladder neck (ROI B). 	
---	--

649 Abbreviations: PFM, pelvic floor muscles; SWE, shear wave elastography; ROI, region of interest.

650

651 **3.5.2 Magnetic resonance imaging (MRI):** is a non-invasive diagnostic technique that produces
652 computerised images of internal body tissues and is based on nuclear magnetic resonance of
653 atoms within the body induced by the application of radio waves⁽¹⁸⁴⁾. **(NEW)** This technique can
654 be applied for many purposes in urology/gynecology/gastroenterology including the assessment
655 of PFM injury, morphometry and positioning of the PFMs and related organs as well as anorectal
656 functioning. Considering that MRI is rarely used in clinic to assess PFM morphometry and
657 function, only a brief overview is provided in Table 19 below and further details are available in
658 other standardization documents^(11,144).

659

660 Table 19. Parameters and findings evaluated with pelvic floor MRI

Parameters, specifications (units of measure) and measurement processes	Outputs and interpretation of findings
<p>3.5.2.1 Levator ani defects: is damage to muscle fibers ranging from disruption of a single fascicle, to complete disruption of the muscle origin (CHANGED)⁽²⁷⁾. FN3.22</p> <p>There is no universally accepted system for the diagnosis and evaluation of the extent of the injury. Essentially, abnormalities are judged to have occurred when the morphology of the pubococcygeal portion of the levator ani muscle deviates from what is seen in normal nulliparous women⁽²⁷⁾.</p>	<p>Levator ani damage on MRI can be diagnosed when one or more of the following is present: absence of pubococcygeal muscle fibers in at least one 4-mm section, or two or more adjacent 2-mm sections in both the axial and the coronal planes⁽²⁷⁾.</p> <p>Defect severity may be further scored in each muscle from 0 (no defect) to 3 (complete loss). A summed score for the two sides (0–6) is assigned and grouped as minor (0–3) or major (4–6)⁽¹¹⁾.</p>
<p>3.5.2.2 Levator ani position in the pelvis: location of the levator ani in the sagittal plane in relation to defined landmarks and reference points/lines⁽¹⁴⁴⁾. (NEW)</p>	<p>May be normal, elevated or descended⁽²⁷⁾.</p>
<p>3.5.2.3 Hiatal dimension: see 3.5.1.3.11</p>	<p>See 3.5.1.3.11</p>
<p>3.5.2.4 MR defecography: demonstrates the anatomy of the anorectum as well as disorders of rectal evaluation. Barium paste is inserted prior to defecation over a translucent commode (CHANGED)⁽⁴²⁾.</p>	<p>This assessment focusses on anorectal function. When dyssynergia is diagnosed (see definition 4.3.1) this confirms PFM involvement⁽¹¹⁾</p>

661 Abbreviations: MRI, magnetic resonance imaging; PFM, pelvic floor muscles.

662

663 **3.6 Algometry:** a test to assess the pain response to application of blunt pressure. It is used to
 664 evaluate the pain threshold and pain tolerance. **(NEW)**. Responses may reflect increased sensitivity
 665 (allodynia, hyperalgesia, hyperpathia) or loss of sensation. Algometry does not provide objective
 666 information regarding pathology or neurophysiological function, as do other more sophisticated
 667 quantitative sensory testing methods.

668

669 Parameters and findings evaluated with algometry are described in Table 20.

670

671 Table 20. Parameters and findings evaluated with algometry

Parameters, specifications (units of measure) and measurement processes	Outputs and interpretation of findings
<p>3.6.1 Algometer/Algesiometer: an instrument for measuring the pain response to a pressure stimulus. (NEW)</p> <p>An algometry device measures pressure applied in Newtons or kg/cm², with an associated patient-reported pain response.</p> <ul style="list-style-type: none"> To assess vulval or vestibular pressure pain response, the assessor uses an algometer⁽¹⁸⁶⁾ or a syringe with a pre-loaded or pre-set amount of pressure, called a vulvalgesiometer⁽¹⁸⁷⁾ or a cotton swab⁽¹⁸⁸⁾ against the vulval tissue and delivers the pressure. <p>To assess intra-vaginal pressure pain response, the assessor mounts a digital palpometer (sensor) to the palpating digit, covered by examination glove, and connected to an algometry device. The device applies a pre-set amount of pressure to the tissue⁽¹⁸⁸⁻¹⁹⁰⁾. To assess pressure/pain in pelvic floor tissues, the assessor applies a pre-set amount of pressure (usually in the range of 0.5N – 2N^(188,191,192)),</p>	<p>Results may be expressed as the pressure applied when the patient reports detection or tolerance of pain, or a specific pressure applied and the patient rating of pain at that pressure. A finding of pain with a low applied pressure may suggest allodynia, and a finding of pain with a moderate applied pressure may suggest hyperalgesia.</p>

<p>starting at a low pressure and assesses pain response to that pressure, or applying increasing amounts of pressure and instructing the patient to state when the pressure reaches the patient's threshold.</p> <p>Algometry tests:</p> <ul style="list-style-type: none"> • 3.6.1.1 Pressure pain threshold (PPT): the minimum intensity of a pressure stimulus that is perceived as painful⁽¹⁹³⁾. (i.e. point at which a sensation changes from one of pressure to one of pain) (NEW). • 3.6.1.2 Pressure pain tolerance (PPTol): the highest intensity of painful pressure stimulus that an individual is able to tolerate⁽¹⁹³⁾. (NEW). 	<p>Variability in readings can be caused by: anatomical test site (muscle belly vs. tendon⁽¹⁹⁴⁾; mucosa vs. tendon⁽¹⁹¹⁾, co-existence of other pain disorders⁽¹⁹⁵⁾; left vs. right⁽¹⁹⁶⁾, stage in menstrual cycle⁽¹⁹⁷⁾, sex and gender⁽¹⁹⁸⁾, rate of pressure increase during test, dimensions of the pressure applicator.</p>
--	--

672

FN3.1 See section 2.2.9 for definition.

FN3.2 Using the dynamometer alone, the stiffness value will reflect the summative contribution of the active and passive components of tone. If dynamometry is combined with EMG, the passive contribution can be identified⁽⁸⁶⁾.

FN3.3 This term refers to simple manometry that measures pressure in the anal sphincter. This is differentiated from sophisticated anorectal manometry – see Section 3.3.2.

FN3.4 It is not recommended to use intravaginal pressure manometry to assess the reflex contraction of the PFM during coughing⁽⁹⁹⁾. Bo and Constantinou⁽⁹⁹⁾ explained that pressure measurement is a summation of signals including PFM and intra-abdominal pressure caused by the cough itself and therefore, it is unlikely that the PFM reflex can be assessed in isolation using pressure manometry. In contrast, ano-rectal manometry can be used to assess a reflex during an involuntary PFM contraction⁽¹⁰⁰⁾ if the transducer is located in the anus, caudal to the puborectalis/ano-rectal junction; therefore it is not impacted directly by intra-abdominal pressure.

FN3.5 This investigation is termed 'anal manometry' in Sultan et al⁽¹¹⁾

FN3.6 This is not an exhaustive list of anorectal manometry parameters.

FN3.7 This contrast with vaginal manometry where the source of pressure during an involuntary contraction cannot be assumed to be the levator ani contraction.

FN3.8 Clinical EMG devices mainly offer pre-set filter settings.

FN3.9 Reducing the size of electrode and the inter-electrode distance may increase the system selectivity and reduce cross talk⁽¹¹⁸⁾.

FN3.10 The recording of resting activity is highly susceptible to contamination by ambient noise. A low proportion of noise in the signal (or higher signal-to-noise ratio) is necessary for accurate assessment.

FN3.11 Unlike many other skeletal muscles^(123,124), the PFMs are thought to have a level of constant EMG activity in order to maintain continence and support of pelvic/abdominal contents.

FN3.12 Advanced EMG techniques are needed to prevent inaccurate interpretation from artefacts and muscle crosstalk.

FN3.13 Slow recruitment could be a sign of PFM dysfunction if it leads to leakage during coughing and sneezing when a quick muscle contraction is needed to counteract increased intra-abdominal pressure^(27,75).

FN3.14 The definition for this term used in Bo et al⁽²⁷⁾ is the definition this document calls ‘slow reaction time’.

FN3.15 This may also be considered in the motor control domain.

FN3.16 Factors that may compromise the measurement of bladder base displacement include: the lack of bony landmark as a fixed starting point and the fact that movement of the bladder base does not always reflect movement of the bladder neck⁽¹³⁵⁾.

FN3.17 This finding must be correlated with findings of other tests and signs (especially digital vaginal / rectal palpation) to determine reason for asymmetry.

FN3.18 Factors that may affect the measurement of bladder base displacement include: the lack of bony landmark as a fixed starting point and the fact that movement of the bladder base does not always reflect movement of the bladder neck⁽¹³⁵⁾.

3.19 An endocavity probe consists of an elongated probe used to perform endovaginal or endorectal examination.

FN3.20 The horizontal reference line drawn from antero-posterior margin or the lowest margin of the PS may be influenced by the angle of the transducer.

FN3.21 Synonyms are puborectalis/pubovisceralis defects or injury.

FN3.22 The term levator injury is also used synonymously^(11,185).

673

674 **SECTION 4: DIAGNOSES**

675 **Diagnosis:** the act or process of identifying or determining the nature and cause of a disease or injury
676 through evaluation of patient history, examination, review of investigations, and the opinion derived
677 from such an evaluation⁽¹⁹⁹⁾. **(CHANGED)** The diagnostic process aims to identify the most specific
678 disorder possible. Overarching diagnoses are used when there is less certainty about the presenting
679 disorder. Diagnoses that are specific to the PFMs may co-exist with and be used in addition to other
680 pelvic floor diagnoses the patient presents with, e.g. voiding dysfunction, pelvic organ prolapse. The
681 diagnoses proposed below may change as evidence emerges to support or refute these terms as
682 diagnostic terms. In some healthcare settings, clinicians are required to assign a code for the presenting
683 diseases, disorders, injuries and other related health conditions, using the International Classification
684 of Diseases (ICD) coding system⁽²⁰⁰⁾. Not all terms below have a corresponding ICD diagnostic code.
685 As advised by ICD, “codes that describe symptoms and signs, as opposed to diagnoses, are acceptable
686 for reporting purposes when a related definitive diagnosis has not been established (confirmed) by the
687 provider”.

688

689 **4.0. Pelvic floor muscle disorder/dysfunction:** an alteration of normal PFM function. **(NEW)** Any
690 departure from normal function of the PFM that is of bother to the patient and has an associated sign
691 and/or a finding from an investigation that suggests a departure from normal structure or function. If a
692 specific disorder can be diagnosed, the following terms may be used.

693

694 **4.1 Disorder of increased PFM tone**

695 **4.1.1 Pelvic floor tension myalgia:** a condition of pain and increased PFM tone **(NEW)**.^{FN4.1} If
696 the location can be confirmed as the levator ani, then the term can be levator ani tension myalgia.
697 Criteria for diagnosis of pelvic floor tension myalgia are described in Table 21.

699 Table 21: Criteria for diagnosis of pelvic floor tension myalgia

Assessment	Findings
Symptoms	<ul style="list-style-type: none"> • may relate to sensation of pain: pain, tender, ache, discomfort • may relate to sensation of increased tone: tight, tense, narrow or constricted
Signs	<p>tenderness or tender point on palpation of PFM_s FN4.2 per perineum, per vaginam or per rectum</p> <p>as well one or more of the following signs:</p> <ul style="list-style-type: none"> • lack of perineal and/or PFM descent with sustained increased intra-abdominal pressure • absent, partial or delayed relaxation of perineum and/or PFM after contraction • non-relaxing PFM • hypertonicity, or increased PFM tone, on a continuum from transient increase in tone to spasm • fasciculation • reduced flexibility of the vaginal opening
Investigations	<p>muscle tenderness as assessed by digital algometry (palpometry)</p> <p>finding of increased tone from any tool which measures tone (dynamometry, myotonometry, manometry, EMG, ultrasound or MRI).</p> <ul style="list-style-type: none"> • if EMG reveals an inconsistent or elevated resting baseline, or slow de-recruitment, this suggests increased myoelectrical activity, which may be termed overactivity in the PFM FN4.3.

700 Abbreviations: PFM, pelvic floor muscles; MRI, magnetic resonance; EMG, electromyography

702 **4.1.2 Pelvic floor myofascial pain syndrome:** a pelvic floor pain syndrome of myofascial
 703 origin. **(NEW)** this diagnosis has trigger points as a hallmark feature⁽⁵⁰⁾. However there is no
 704 consensus of the definition and diagnostic criteria associated with trigger points^(50,51). The criteria
 705 most consistently used for diagnosis amongst researchers and expert clinicians are shown in
 706 Table 22.

707
 708 Table 22: Criteria for diagnosis of pelvic floor myofascial pain syndrome

Assessment	Findings
Symptoms	presence of pain
Signs	tender point in a taut band (localized increased tone) of skeletal muscle ^(50,51)
	patient pain recognition on tender point palpation
	referral pattern
	local twitch response
	the paired criteria of tender points in taut bands and predicted or recognised pain referral form the most frequently cited combination of diagnostic criteria
Investigations	there is no consensus regarding objective laboratory tests for myofascial trigger point diagnosis however MR elastography and ultrasound elastography have been reported to investigate myofascial taut bands ⁽²⁰²⁾ and trigger points ⁽²⁰³⁾ in the trapezius muscle.

709 Abbreviations: MR, magnetic resonance

710

711 **4.2 Disorder of PFM pain**

712 **4.2.1 Pelvic floor myalgia:** a condition of PFM pain. **(NEW)**. Criteria for diagnosis of pelvic
 713 floor myalgia are described in Table 23.

714

715 Table 23: Criteria for diagnosis of pelvic floor myalgia

Assessment	Findings
Symptoms	pain, tender, ache, discomfort
Signs	muscle tenderness or tender point on palpation of PFM _s FN4.4 and normal tone in PFM <i>per perineum, per vaginam</i> or <i>per rectum</i> .
Investigations	muscle tenderness as assessed by digital algometry (palpometry)
	finding of normal tone (measured by dynamometry, myotonometry, manometry, EMG, ultrasound or MRI)

716 Abbreviations: PFM, pelvic floor muscles, EMG, electromyography; MRI, magnetic resonance
 717 imaging.

718

719 **4.3 Disorder of decreased PFM tone:** a condition which results from a reduction in PFM tone,
 720 due to either the contractile or the non-contractile components of tone FN4.5. **(NEW)**. Criteria for
 721 diagnosis of decreased PFM tone are described in Table 24.

722

723 Table 242: Criteria for diagnosis of decreased PFM tone

Assessment	Findings
Symptoms	loose, lax, gaping, sagging, open, weak, bulging, full, loss of control
Signs	hypotonicity, decreased PFM tone, anal or introital gaping, excessive flexibility of the vaginal opening, palpation of an anal sphincter gap or levator avulsion.
	deficit in PFM contractile function: absence of voluntary PFM contraction, decreased strength (weakness), decreased sustained and repeated endurance, lack of perineal or PFM elevation, no urethral lift, partial or uncertain levator closure, small to no change in levator hiatus on contraction.

Investigations	any tool which measures tone (measured by dynamometry, myotonometry, manometry, EMG, ultrasound or MRI)
	- if EMG reveals a reduced signal amplitude or peak microvolts, or shorter duration of sustained contraction this suggests decreased myoelectrical activity, which may be termed ‘underactivity’ in the PFM. FN4.6

724 Abbreviations: PFM, pelvic floor muscles; EMG, electromyography; MRI, magnetic resonance
725 imaging.

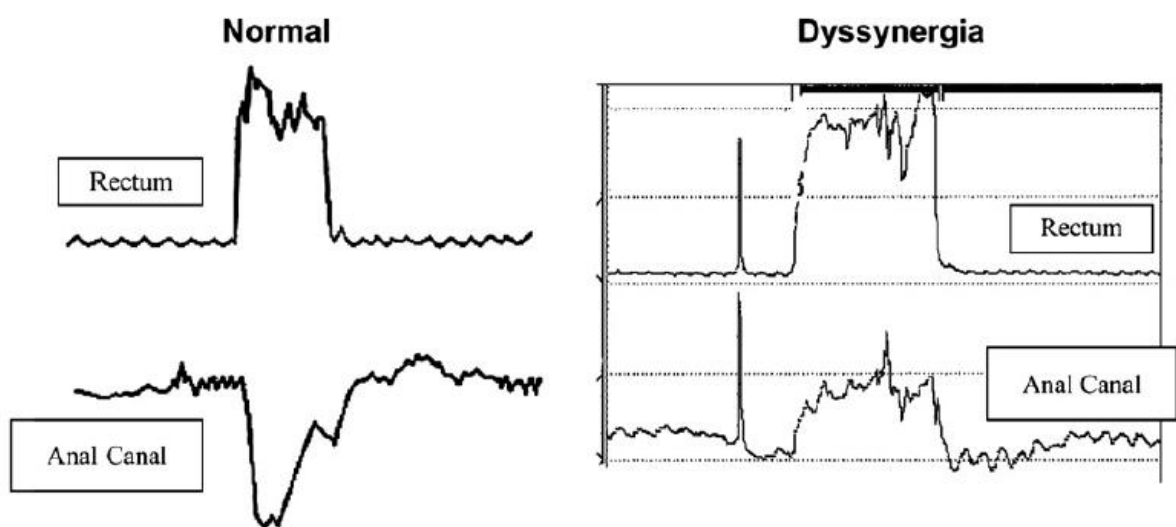
726

727 4.4 Disorder of PFM coordination

728 **4.4.1 PFM dyssynergia** FN4.7 paradoxical PFM or sphincter contraction: a dysfunction of
729 coordination between the PFM and a functional activity, such as a PFM contraction when
730 relaxation is functionally required. **(NEW)**. These dyssynergias may share similar symptoms
731 and signs FN4.8, FN4.9

732 **4.4.1.1 Anismus:** spasm of the EAS with attempted defecation or anal penetration
733 **(CHANGED)**⁽¹¹⁾. FN4.10 This dyssynergia is shown in Figure 12.

734



735

736 Figure 12: A normal and abnormal (dyssynergic) pattern of defecation, from Rao 2007⁽²⁰⁴⁾. A
737 normal pattern consists of a rise in the intrarectal pressure coordinated with relaxation of anal

738 sphincter pressure. In contrast, a dyssynergic pattern is associated with a paradoxical increase
 739 in anal sphincter pressure. Typical patterns for a normal and dyssynergic pattern of defecation
 740 as measured during anorectal manometry with a pressure sensor in the rectum and a pressure
 741 sensor in the anal canal.

742 Criteria for diagnosis of anismus are described in Table 25.

743

744 Table 25: Criteria for diagnosis of anismus

Assessment	Findings
Symptoms	pain, tender, ache, discomfort during attempted defecation or anal penetration
Signs	perineal and / or PFM elevation with sustained increased IAP (bearing down) or attempted penetration
	Increased PFM tone
Investigations	balloon expulsion test
	MR defecography
	EMG: PFM activation during defecation suggesting poor motor control ⁽²⁰⁵⁾

745 Abbreviations: PFM, pelvic floor muscles; IAP, intra-abdominal pressure; MR, magnetic resonance;
 746 EMG, electromyography.

747

748 **4.4.1.2 Vaginismus:** spasm of vaginal musculature that interferes with vaginal penetration
 749 **(CHANGED)**⁽¹²⁾. FN4.11 Criteria for diagnosis of vaginismus are described in Table 26.

750 Vaginismus may also be termed genito-pelvic pain/penetration disorder, which includes fear
 751 or anxiety as a component of the disorder^(206,207).

752

753 Table 26: Criteria for diagnosis of vaginismus

Assessment	Findings
Symptoms	pain, tight, tense, narrow or constricted
Signs	transient increased tone - inability to maintain relaxation with attempted vaginal penetration
	increased PFM tone
Investigations FN4.12	assessment of resting tone (measured by dynamometry, myotonometry, manometry, EMG, ultrasound or MRI)
	increased activation of PFM shown by perineal or peri-anal EMG during attempted vaginal penetration.

754 Abbreviations: PFM, pelvic floor muscles; EMG, electromyography; MRI, magnetic resonance
755 imaging.

756

757 **4.5 Pudendal neuralgia:** Pudendal neuralgia is a chronic and severely disabling neuropathic pain
758 syndrome caused by mechanical or non-mechanical injury of the pudendal nerve⁽²⁰⁸⁾. **(NEW)** The
759 Nantes criteria list 5 essential diagnostic criterion including 3 symptoms, one sign and one
760 investigation⁽²⁰⁹⁾. These criteria are described in Table 27.

761

762 Table 27: Criteria for diagnosis of pudendal neuralgia

Assessment	Findings
Symptoms	pain in the distribution of the pudendal nerve and it's referral areas, primarily the genitalia including the vulvovaginal, anorectal and distal urethral areas.
	worse in the sitting position
	pain does not wake the patient at night, no numbness of the perineum
	the patient may also have associated pelvic floor symptoms ⁽²⁰⁸⁾

Signs	Nantes criteria ⁽²⁰⁹⁾ sign: no loss of sensation in the pudendal distribution on objective testing
	<p>Other signs include</p> <ul style="list-style-type: none"> • tenderness to palpation anywhere along the length of the pudendal nerve • increased tone and tenderness of the obturator internus or piriformis muscles (depending on the location of the nerve irritation) • positive pudendal nerve neurodynamic test • positive pudendal nerve provocation test
Investigations	As per Nantes criteria ⁽²⁰⁹⁾ : may be confirmed by relief of patient's pain after a pudendal nerve block with or without guided imaging. FN4.13

763

FN4.1 This term was first used by Sinaki et al 1977⁽²⁰¹⁾, however in their case series, they did not assess PFM tone or tension. Nevertheless, they proposed the cause of the pain was “habit contraction or chronic spasm of the PFM”. We propose that this term should be used only when both pain and increased tone are present.

FN4.2 When assessing sensory changes *PV* or *PR*, the clinician needs to determine whether s/he is detecting sensory change in the mucosa (mucosal sensitivity), or the underlying muscle (muscle tenderness) by differentiating the depth and firmness of palpation.

FN4.3 The previously proposed term ‘overactive PFM’⁽²⁶⁾ has been used to refer to increased tone in a muscle, however if the source of the increased tone (contractile or noncontractile component of tone) cannot be determined, this term is not recommended.

FN4.4 When assessing sensory changes *PV* or *PR*, the clinician needs to determine whether s/he is detecting sensory change in the mucosa (mucosal sensitivity), or the underlying muscle (muscle tenderness) by differentiating the depth and firmness of palpation.

FN4.5 It may be impossible to distinguish between the 2 subsets of this condition without access to an investigation which is able to separate the measurement of the contractile from the non-contractile components of tone. Even so, the certainty of the contribution from the contractile component of tone recorded by sEMG needs to consider the limitations of sEMG findings (noise, cross-talk etc).

FN4.6 The previously proposed term ‘underactive PFM’⁽²⁶⁾ has been used to refer to decreased tone in a muscle, however if the source of the decreased tone (contractile or noncontractile component of tone) cannot be determined, this term is not recommended.

FN4.7 Dyssynergia may be similar to the condition termed “overactive pelvic floor muscles” as described by Messelink et al⁽²⁶⁾: “A situation in which the pelvic floor muscles do not relax, or may even contract when relaxation is functionally needed for example during micturition or defecation. This condition is based on symptoms such as voiding problems, obstructed defecation, or dyspareunia and on signs like the absence of voluntary pelvic floor muscle relaxation.”

FN4.8 PFM-related symptoms reported by patients may be secondary to more bothersome functional symptoms such as inability to void, defaecate or allow vaginal entry.

FN4.9 Difficulty voiding may be due to paradoxical contraction of the urethral sphincter, as occurs in conditions such as detrusor sphincter dyssynergia or voiding dysfunction, however there is no apparent PFM-related symptom that the patient reports.

FN4.10 Anismus is the PFM component of dyssynergic defecation. Diagnosis of dyssynergic defecation includes functional constipation criteria, prolonged transit, and ineffective motility to expel feces⁽²⁰⁴⁾.

FN4.11 As stated in Rogers et al⁽¹²⁾, there is often (phobic) avoidance and anticipation/fear/experience of pain, along with variable involuntary PFM contraction. Patients with vaginismus could present with severe fear avoidance without vulvar pain or fear avoidance with vulvar pain. Structural or other physical abnormalities must be ruled out/addressed. There is controversy of whether or not this term should be retained, with the Diagnostic and Statistical Manual of Mental Disorders 2013 proposal to replace dyspareunia and vaginismus with the term “Genito-Pelvic Pain/Penetration Disorder (GPP/PD)”⁽²⁰⁶⁾, and the lack of consensus on this term⁽²⁰⁷⁾.

FN4.12 Investigations may be in-conclusive, as PFM tone values may overlap in conditions such as dyspareunia and vaginismus, therefore the PFM resting tone and response to attempted penetration may not exclusively diagnose vaginismus.

FN4.13 Pudendal nerve blocks are technically difficult to perform accurately and lack of pain relief after the procedure does not rule out the condition⁽²⁰⁸⁾.

764 **CONCLUSION**

765 This report has drawn together the most frequently published methods of PFM assessment that appear
766 in the published literature. This process has highlighted the plethora of terms in current use. We have
767 attempted to provide the most precise yet clinically-meaningful definitions and descriptions of these
768 terms, and where available, provided an explanation of the finding from the assessment method. We
769 hope this will provide clinicians and researchers with clarity and standardisation in the recording of
770 PFM function and dysfunction. It is anticipated that some of these terms will be discarded over time
771 and new terms will emerge, and a revision of this document will be required in the future. It is important
772 to remember that visual observation and digital palpation are subjective forms of assessment, and the
773 assessor must be aware that conclusions of PFM function or dysfunction based on these clinical
774 observations may be uncertain. At present, PFM tone and involuntary action remain less well
775 understood than properties such as strength. Where available, the use of quantitative assessment tools
776 (investigations), may strengthen the certainty of the finding. In some instances, it may not be possible
777 to identify a specific classification of PFM disorder, beyond the first level of diagnosis of ‘PFM
778 disorder’.

779

780 **AREAS FOR FURTHER RESEARCH**

781 A core outcome set for PFM assessment would be valuable, however this requires knowledge of the
782 clinimetric properties of the many assessment methods currently used in clinical practice and research,
783 and a comparison of these properties amongst the assessment methods; such knowledge is lacking.
784 There is an urgent need for a report to compile the validity, reliability and responsiveness of PFM
785 assessment methods, especially for the more subjective methods of visual observation and digital
786 palpation. The clinimetric properties of some aspects of the more objective methods of PFM
787 assessment (simple and sophisticated tools) has been undertaken, however many gaps in testing

788 remain. Whether any of these assessment methods provide diagnostic test accuracy of PFM function
789 and dysfunction is unknown. Future research in this area is required.

790

791

792 **ACKNOWLEDGEMENTS / ADDENDUM/ METHODOLOGY:**

- 793 - Paul McCrory, Neurologist, PhD, Melbourne, Australia
- 794 - Paul Hodges, Physiotherapist, PhD, Brisbane, Australia
- 795 - Ryan Stafford, PhD, Brisbane, Australia
- 796 - Dawson Kidgell, Neuromuscular Physiologist, PhD, Melbourne, Australia
- 797 - Ashlyn Frazer, Human Physiologist, PhD, Melbourne, Australia
- 798 - Hans Peter Dietz, Urogynaecologist, PhD, Sydney, Australia
- 799 - Irmina Nahon, Physiotherapist, PhD, Canberra, Australia
- 800 - Patricia Neumann, Physiotherapist, PhD, Adelaide, Australia
- 801 - Shaza Kadah, Physiotherapist, PhD student, Melbourne, Australia

802



803

804 This document has involved 20 rounds of reviews of individual sections and 11 rounds of full
805 manuscript review by working group members, with co-chair checking, collation and feedback of all
806 comments. Additional multiple rounds of development and refinement were undertaken by the co-
807 chairs in-between section and full working group reviews. The process was subject to live Meetings
808 in Florence (September 2017), Philadelphia (2018) and Gothenburg (2019). Comprehensive and
809 constructive review was undertaken by expert external reviewers, and we thank them for their
810 considered input: Bert Messelink, David Vodusek, Chantale Dumoulin, Margaret Sherburn, Paul
811 Hodges and MJ Strauhal. A further round of revisions was undertaken in response to the external
812 review. Following ICS website publication, there was a further round of review to address membership
813 comments. Version 12 will be submitted for website and NAU journal publication.

814 **References:**

- 815 1. Eizenberg N, Anatomedia, McGraw-Hill E. An@tomedica: a new approach to medical
816 education, developments in anatomy. In. *Anatomedia online*: Richmond, Vic: Anatomedia Pty
817 Ltd. North Ryde, NSW: McGraw-Hill Education.; 2010.
- 818 2. Primal Pictures L. Primal Pictures' 3D real-time. In. *Primal Pictures' 3D real time*: London,
819 Eng.: Primal Pictures.; 2018.
- 820 3. Frawley HC, Neumann P, Delany C. An argument for competency-based training in pelvic
821 floor physiotherapy practice. *Physiother Theory Pract.* 2019;35(12):1117-1130.
- 822 4. AIUM/IUGA. AIUM/IUGA practice parameter for the performance of Urogynecological
823 ultrasound examinations : Developed in collaboration with the ACR, the AUGS, the AUA, and
824 the SRU. *Int Urogynecol J.* 2019;30(9):1389-1400.
- 825 5. Saltiel F, Miranda-Gazzola APG, Vitoria RO, Figueiredo EM. Terminology of Pelvic Floor
826 Muscle Function in Women With and Without Urinary Incontinence: A Systematic Review.
827 *Phys Ther.* 2018;98(10):876-890.
- 828 6. WHO. International classification of functioning, disability, and health : ICF. In: World Health
829 Organization, Geneva; 2001: <https://www.who.int/classifications/icf/en/>.
- 830 7. Saltiel F, Miranda-Gazzola APG, Vitoria RO, Sampaio RF, Figueiredo EM. Linking Pelvic
831 Floor Muscle Function Terminology to the International Classification of Functioning,
832 Disability and Health. *Phys Ther.* 2020; published 2020 Mar23.
- 833 8. FDA. Food and Drug Administration Guidance for Industry on Patient-Reported Outcome
834 Measures: Use in Medical Product Development to Support Labeling Claims. In. Vol 74:
835 Federal Register; 2009:65132-65133.
- 836 9. Johnston B, Patrick D, Devji T, et al. Chapter 18: Patient-reported outcomes. In: Higgins J,
837 Thomas J, Chandler J, et al., eds. *Cochrane Handbook for Systematic Reviews of Interventions*
838 *version 6.0 (updated July 2019)*: Cochrane; 2019.
- 839 10. Melzack R. The short-form McGill Pain Questionnaire. *Pain.* 1987;30(2):191-197.
- 840 11. Sultan AH, Monga A, Lee J, et al. An International Urogynecological Association
841 (IUGA)/International Continence Society (ICS) Joint Report on the Terminology for Female
842 Anorectal Dysfunction. *Neurourol Urodyn.* 2017;36(1):10-34.
- 843 12. Rogers RG, Pauls RN, Thakar R, et al. An International Urogynecological Association
844 (IUGA)/International Continence Society (ICS) joint report on the terminology for the
845 assessment of sexual health of women with pelvic floor dysfunction. *Neurourol Urodyn.*
846 2018;37(4):1220-1240.
- 847 13. Neels H, Mortiers X, de Graaf S, Tjalma WAA, De Wachter S, Vermandel A. Vaginal wind:
848 A literature review. *Eur J Obstet Gynecol Reprod Biol.* 2017;214:97-103.
- 849 14. Bottomley JM. *Quick reference dictionary for physical therapy.* 3rd edition ed. Thorofare:
850 Slack; 2013.
- 851 15. Slade SC, Dionne CE, Underwood M, Buchbinder R. Consensus on Exercise Reporting
852 Template (CERT): Explanation and Elaboration Statement. *Br J Sports Med.*
853 2016;50(23):1428-1437.
- 854 16. Slieker-ten Hove MC, Pool-Goudzwaard AL, Eijkemans MJ, Steegers-Theunissen RP, Burger
855 CW, Vierhout ME. Face validity and reliability of the first digital assessment scheme of pelvic
856 floor muscle function conform the new standardized terminology of the International
857 Continence Society. *Neurourol Urodyn.* 2009;28(4):295-300.
- 858 17. Shelly B, Dunbar A. Palpation and assessment of the pelvic floor muscles using depth and
859 positional measurements. *Journal of the Section on Women's Health.* 2004;28(1):19-23.
- 860 18. Haylen BT, Maher CF, Barber MD, et al. An International Urogynecological Association
861 (IUGA) / International Continence Society (ICS) Joint Report on the Terminology for Female
862 Pelvic Organ Prolapse (POP). *Neurourol Urodyn.* 2016;35(2):137-168.

- 863 19. Geller EJ, Robinson BL, Matthews CA, et al. Perineal body length as a risk factor for
864 ultrasound-diagnosed anal sphincter tear at first delivery. *Int Urogynecol J*. 2014;25(5):631-
865 636.
- 866 20. Lane TL, Chung CP, Yandell PM, Kuehl TJ, Larsen WI. Perineal body length and perineal
867 lacerations during delivery in primigravid patients. *Proc (Bayl Univ Med Cent)*.
868 2017;30(2):151-153.
- 869 21. Oettle GJ, Roe AM, Bartolo DC, Mortensen NJ. What is the best way of measuring perineal
870 descent? A comparison of radiographic and clinical methods. *Br J Surg*. 1985;72(12):999-
871 1001.
- 872 22. Savoye-Collet C, Savoye G, Koning E, Leroi AM, Dacher JN. Gender influence on
873 defecographic abnormalities in patients with posterior pelvic floor disorders. *World J*
874 *Gastroenterol*. 2010;16(4):462-466.
- 875 23. Ambrose S, Keighley MR. Outpatient measurement of perineal descent. *Ann R Coll Surg Engl*.
876 1985;67(5):306-308.
- 877 24. Henry MM. Anorectal physiology and pelvic floor disorders. *Curr Opin Gastroenterol*.
878 1986;2(1):44-46.
- 879 25. Mazier WP. Keyhole deformity. Fact and fiction. *Dis Colon Rectum*. 1985;28(1):8-10.
- 880 26. Messelink B, Benson T, Berghmans B, et al. Standardization of terminology of pelvic floor
881 muscle function and dysfunction: report from the pelvic floor clinical assessment group of the
882 International Continence Society. *Neurourol Urodyn*. 2005;24(4):374-380.
- 883 27. Bø K, Frawley HC, Haylen BT, et al. An International Urogynecological Association
884 (IUGA)/International Continence Society (ICS) joint report on the terminology for the
885 conservative and nonpharmacological management of female pelvic floor dysfunction.
886 *Neurourol Urodyn*. 2017;36(2):221-244.
- 887 28. Stafford RE, Coughlin G, Lutton NJ, Hodges PW. Validity of Estimation of Pelvic Floor
888 Muscle Activity from Transperineal Ultrasound Imaging in Men. *PLoS One*.
889 2015;10(12):e0144342.
- 890 29. Neumann PB, O'Callaghan M. The Role of Preoperative Puborectal Muscle Function Assessed
891 by Transperineal Ultrasound in Urinary Continence Outcomes at 3, 6, and 12 Months After
892 Robotic-Assisted Radical Prostatectomy. *Int Neurourol J*. 2018;22(2):114-122.
- 893 30. Stafford RE, van den Hoorn W, Coughlin G, Hodges PW. Postprostatectomy incontinence is
894 related to pelvic floor displacements observed with trans-perineal ultrasound imaging.
895 *Neurourol Urodyn*. 2018;37(2):658-665.
- 896 31. Baessler K, Metz M, Junginger B. Valsalva versus straining: There is a distinct difference in
897 resulting bladder neck and puborectalis muscle position. *Neurourol Urodyn*. 2017;36(7):1860-
898 1866.
- 899 32. Miller JM, Ashton-Miller JA, DeLancey JO. A pelvic muscle precontraction can reduce cough-
900 related urine loss in selected women with mild SUI. *J Am Geriatr Soc*. 1998;46(7):870-874.
- 901 33. Sliker-ten Hove M, Pool-Goudzwaard A, Eijkemans M, Steegers-Theunissen R, Burger C,
902 Vierhout M. Pelvic floor muscle function in a general population of women with and without
903 pelvic organ prolapse. *International Urogynecology Journal*. 2010;21(3):311-319.
- 904 34. IASP. IASP Terminology, in Part III: Pain Terms, A Current List with Definitions and Notes
905 on Usage, Classification of Chronic Pain. In: 2nd edition 1994, 2nd update 2012 ed.
906 [https://www.iasp-](https://www.iasp-pain.org/Education/Content.aspx?ItemNumber=1698&navItemNumber=5762011)
907 [pain.org/Education/Content.aspx?ItemNumber=1698&navItemNumber=5762011](https://www.iasp-pain.org/Education/Content.aspx?ItemNumber=1698&navItemNumber=5762011). Accessed
908 24Jan2020.
- 909 35. Fearmonti R, Bond J, Erdmann D, Levinson H. A review of scar scales and scar measuring
910 devices. *Eplasty*. 2010;10:e43-e43.
- 911 36. Skorupska E, Bednarek A, Samborski W. Tender Points and Trigger Points - Differences and
912 Similarities. *J Musculoskelet Pain*. 2013;21(3):269-275.

- 913 37. Farrar JT, Young JP, LaMoreaux L, Werth JL, Poole RM. Clinical importance of changes in
914 chronic pain intensity measured on an 11-point numerical pain rating scale. *Pain*.
915 2001;94(2):149-158.
- 916 38. Butler D. *The Sensitive Nervous System, ch 5, Neurodynamics*. Adelaide: Noigroup
917 Publications; 2000.
- 918 39. Strauhal MJ, Frahm J, Morrison P, et al. Vulvar Pain: A Comprehensive Review. *JWHPT*.
919 2007;31(3):7-26.
- 920 40. Bergeron S, Binik YM, Khalife S, Pagidas K, Glazer HI. Vulvar vestibulitis syndrome:
921 reliability of diagnosis and evaluation of current diagnostic criteria. *Obstet Gynecol*.
922 2001;98(1):45-51.
- 923 41. Previnaire JG. The importance of the bulbocavernosus reflex. *Spinal cord series and cases*.
924 2018;4:2-2.
- 925 42. D'Ancona C, Haylen B, Oelke M, et al. The International Continence Society (ICS) report on
926 the terminology for adult male lower urinary tract and pelvic floor symptoms and dysfunction.
927 *Neurourol Urodyn*. 2019;38(2):433-477.
- 928 43. Doggweiler R, Whitmore KE, Meijlink JM, et al. A standard for terminology in chronic pelvic
929 pain syndromes: A report from the chronic pelvic pain working group of the international
930 continence society. *Neurourol Urodyn*. 2017;36(4):984-1008.
- 931 44. Popeney C, Ansell V, Renney K. Pudendal entrapment as an etiology of chronic perineal pain:
932 Diagnosis and treatment. *Neurourol Urodyn*. 2007;26(6):820-827.
- 933 45. Apte G, Nelson P, Brismee JM, Dedrick G, Justiz R, Sizer PS. Chronic Female Pelvic Pain Part
934 1: Clinical Pathoanatomy and Examination of the Pelvic Region. *Pain Practice*. 2012;12(2):88-
935 110.
- 936 46. Neumann P, Sutherland P, Nahon I, Morrison S. Pelvic floor muscle training after prostate
937 surgery. *Lancet*. 2012;379(9811):119; author reply 121.
- 938 47. Allen D, Widener G. Tone abnormalities. In: Cameron M, ed. *Physical Agents in*
939 *Rehabilitation: from research to practice*. 3rd ed. St. Louis, MO, USA: Saunders Elsevier;
940 2009:78.
- 941 48. Simons DG, Mense S. Understanding and measurement of muscle tone as related to clinical
942 muscle pain. *Pain*. 1998;75(1):1-17.
- 943 49. Masi AT, Hannon JC. Human resting muscle tone (HRMT): Narrative introduction and modern
944 concepts. *J Bodyw Mov Ther*. 2008;12(4):320-332.
- 945 50. Tough EA, White AR, Richards S, Campbell J. Variability of criteria used to diagnose
946 myofascial trigger point pain syndrome--evidence from a review of the literature. *Clin J Pain*.
947 2007;23(3):278-286.
- 948 51. Bourgaize S, Janjua I, Murnaghan K, Mior S, Srbely J, Newton G. Fibromyalgia and
949 myofascial pain syndrome: Two sides of the same coin? A scoping review to determine the
950 lexicon of the current diagnostic criteria. *Musculoskeletal Care*. 2019;17(1):3-12.
- 951 52. Kavvadias T, Pelikan S, Roth P, Baessler K, Schuessler B. Pelvic floor muscle tenderness in
952 asymptomatic, nulliparous women: topographical distribution and reliability of a visual
953 analogue scale. *Int Urogynecol J*. 2013;24(2):281-286.
- 954 53. Devreese A, Staes F, De Weerd W, et al. Clinical evaluation of pelvic floor muscle function
955 in continent and incontinent women. *Neurourol Urodyn*. 2004;23(3):190-197.
- 956 54. Dietz HP. The quantification of levator muscle resting tone by digital assessment. *Int*
957 *Urogynecol J*. 2008;19(11):1489.
- 958 55. Reissing ED, Binik YM, Khalife S, Cohen D, Amsel R. Vaginal spasm, pain, and behavior: an
959 empirical investigation of the diagnosis of vaginismus. *Arch Sex Behav*. 2004;33(1):5-17.
- 960 56. Lance JW, McLeod JG. *A physiological approach to clinical neurology*. 3rd ed. London; Boston:
961 Butterworths; 1981.

- 962 57. NINDS. National Institute of Neurological Disorders and Stroke: Dystonia.
 963 [https://www.ninds.nih.gov/Disorders/Patient-Caregiver-Education/Fact-Sheets/Dystonias-](https://www.ninds.nih.gov/Disorders/Patient-Caregiver-Education/Fact-Sheets/Dystonias-Fact-Sheet)
 964 [Fact-Sheet](https://www.ninds.nih.gov/Disorders/Patient-Caregiver-Education/Fact-Sheets/Dystonias-Fact-Sheet). Accessed 27Sep2020.
- 965 58. Gentilcore-Saulnier E, McLean L, Goldfinger C, Pukall CF, Chamberlain S. Pelvic floor
 966 muscle assessment outcomes in women with and without provoked vestibulodynia and the
 967 impact of a physical therapy program. *J Sex Med.* 2010;7(2 Pt 2):1003-1022.
- 968 59. van Delft K, Shobeiri SA, Thakar R, Schwertner-Tiepelmann N, Sultan AH. Intra- and
 969 interobserver reliability of levator ani muscle biometry and avulsion using three-dimensional
 970 endovaginal ultrasonography. *Ultrasound Obstet Gynecol.* 2014;43(2):202-209.
- 971 60. Rao SSC. Rectal Exam: Yes, it can and should be done in a busy practice! *Am J Gastroenterol.*
 972 2018;113(5):635-638.
- 973 61. Bo K, Finckenhagen HB. Vaginal palpation of pelvic floor muscle strength: inter-test
 974 reproducibility and comparison between palpation and vaginal squeeze pressure. *Acta Obstet*
 975 *Gynecol Scand.* 2001;80(10):883-887.
- 976 62. Deegan EG, Stothers L, Kavanagh A, Macnab AJ. Quantification of pelvic floor muscle
 977 strength in female urinary incontinence: A systematic review and comparison of contemporary
 978 methodologies. *Neurourol Urodyn.* 2018;37(1):33-45.
- 979 63. Van Kampen M, De Weerd W, Feys H, Honing S. Reliability and validity of a digital test for
 980 pelvic muscles strength in women. *Neurourol and Urodynam* 1996;15:338-336.
- 981 64. Laycock J, Jerwood D. Pelvic Floor Muscle Assessment: The PERFECT Scheme.
 982 *Physiotherapy.* 2001;87(12):631-642.
- 983 65. Brink CA, Sampsel CM, Wells TJ, Diokno AC, Gillis GL. A digital test for pelvic muscle
 984 strength in older women with urinary incontinence. *Nurs Res.* 1989;38(4):196-199.
- 985 66. Draper N, Marshall H. In: *Exercise Physiology for Health and Sports Performance.* 1st edition
 986 ed.2012:206.
- 987 67. Plowman D, Smith D. *Exercise physiology for health, fitness, and performance.* Philadelphia:
 988 Wolters Kluwer Health /Lippincott Williams & Wilkins Health; 2014.
- 989 68. Schabrun SM, Stafford RE, Hodges PW. Anal sphincter fatigue: is the mechanism peripheral
 990 or central? *Neurourol Urodyn.* 2011;30(8):1550-1556.
- 991 69. Kent M. *The Oxford Dictionary of Sports Science & Medicine.* 3 ed: Oxford University Press
 992 Print Publication 2006.
- 993 70. Milios JE, Ackland TR, Green DJ. Pelvic floor muscle training in radical prostatectomy: a
 994 randomized controlled trial of the impacts on pelvic floor muscle function and urinary
 995 incontinence. *BMC Urol.* 2019;19(1):116.
- 996 71. Boyles SH, Edwards SR, Gregory WT, Denman MA, Clark AL. Validating a clinical measure
 997 of levator hiatus size. *Am J Obstet Gynecol.* 2007;196(2):174 e171-174.
- 998 72. Keshwani N, McLean L. State of the art review: Intravaginal probes for recording
 999 electromyography from the pelvic floor muscles. *Neurourol Urodyn.* 2015;34(2):104-112.
- 1000 73. Barbosa PB, Franco MM, Souza Fde O, Antonio FI, Montezuma T, Ferreira CH. Comparison
 1001 between measurements obtained with three different perineometers. *Clinics (Sao Paulo).*
 1002 2009;64(6):527-533.
- 1003 74. Dumoulin C, Gravel D, Bourbonnais D, Lemieux MC, Morin M. Reliability of dynamometric
 1004 measurements of the pelvic floor musculature. *Neurourol Urodyn.* 2004;23(2):134-142.
- 1005 75. Castro Dias D, Robinson D, Bosch R, et al. Initial assessment of urinary incontinence in adult
 1006 male and female patients. In: Abrams P, Cardoso L, Wagg A, Wein A, eds. *Incontinence, 6th*
 1007 *International Consultation on Incontinence.* Tokyo: ICUD ICS; 2017:2619.
- 1008 76. Caufriez M. Postpartum. Rééducation urodynamique. Approche globale et technique
 1009 analytique. In: *Book chapter:2.* Vol Tome 3. Brussels, Belgium: Collection Maïte; 1993:36-
 1010 44.

- 1011 77. Ashton-Miller JA, DeLancey JOL, Warwick DN, Inventors. Method and apparatus for
 1012 measuring properties of the pelvic floor muscles. 2002.
- 1013 78. Dumoulin C, Bourbonnais D, Lemieux MC. Development of a dynamometer for measuring
 1014 the isometric force of the pelvic floor musculature. *Neurourol Urodyn.* 2003;22(7):648-653.
- 1015 79. Morin M, Dumoulin C, Gravel D, Bourbonnais D, Lemieux MC. Reliability of speed of
 1016 contraction and endurance dynamometric measurements of the pelvic floor musculature in
 1017 stress incontinent parous women. *Neurourol Urodyn.* 2007;26(3):397-403; discussion 404.
- 1018 80. Parezanovic-Ilic K, Jevtic M, Jeremic B, Arsenijevic S. [Muscle strength measurement of
 1019 pelvic floor in women by vaginal dynamometer]. *Srp Arh Celok Lek.* 2009;137(9-10):511-517.
- 1020 81. Kruger JA, Nielsen PM, Budgett SC, Taberner AJ. An automated hand-held elastometer for
 1021 quantifying the passive stiffness of the levator ani muscle in women. *Neurourol Urodyn.*
 1022 2015;34(2):133-138.
- 1023 82. Nunes FR, Martins CC, Guirro EC, Guirro RR. Reliability of bidirectional and variable-
 1024 opening equipment for the measurement of pelvic floor muscle strength. *PM R.* 2011;3(1):21-
 1025 26.
- 1026 83. Romero-Culleres G, Peña Pitarch E, Jane Feixas C, et al. Reliability and validity of a new
 1027 vaginal dynamometer to measure pelvic floor muscle strength in women with urinary
 1028 incontinence. *Neurourol Urodyn.* 2013;32(658-659).
- 1029 84. Morin M, Gravel D, Bourbonnais D, Dumoulin C, Ouellet S. Reliability of dynamometric
 1030 passive properties of the pelvic floor muscles in postmenopausal women with stress urinary
 1031 incontinence. *Neurourol Urodyn.* 2008;27(8):819-825.
- 1032 85. Morin M, Gravel D, Bourbonnais D, Dumoulin C, Ouellet S, Pilon JF. Application of a new
 1033 method in the study of pelvic floor muscle passive properties in continent women. *J*
 1034 *Electromyogr Kinesiol.* 2010;20(5):795-803.
- 1035 86. Morin M, Binik YM, Bourbonnais D, Khalife S, Ouellet S, Bergeron S. Heightened Pelvic
 1036 Floor Muscle Tone and Altered Contractility in Women With Provoked Vestibulodynia. *J Sex*
 1037 *Med.* 2017;14(4):592-600.
- 1038 87. Gajdosik RL. Passive extensibility of skeletal muscle: review of the literature with clinical
 1039 implications. *Clin Biomech.* 2001;16:87-101.
- 1040 88. Magnusson SP. Passive properties of human skeletal muscle during stretch maneuvers. A
 1041 review. *Scand J Med Sci Sports.* 1998;8(2):65-77.
- 1042 89. Agyapong-Badu S, Warner M, Samuel D, Narici M, Cooper C, Stokes M. Anterior thigh
 1043 composition measured using ultrasound imaging to quantify relative thickness of muscle and
 1044 non-contractile tissue: a potential biomarker for musculoskeletal health. *Physiol Meas.*
 1045 2014;35(10):2165-2176.
- 1046 90. Aird L, Samuel D, Stokes M. Quadriceps muscle tone, elasticity and stiffness in older males:
 1047 reliability and symmetry using the MyotonPRO. *Arch Gerontol Geriatr.* 2012;55(2):e31-39.
- 1048 91. Bailey L, Dinesh S, Warner M, Stokes M. Parameters representing muscle tone, elasticity and
 1049 stiffness of biceps brachii in healthy older males: Symmetry and within-session reliability using
 1050 the MyotonPRO. *J Neurol Disord.* 2013;1(16).
- 1051 92. Myoton_AS. MyotonPro User Manual. In: Myoton Muscle Diagnostics; 2018.
- 1052 93. Agyapong-Badu S, Warner M, Samuel D, Stokes M. Practical considerations for standardized
 1053 recording of muscle mechanical properties using a myometric device: Recording site, muscle
 1054 length, state of contraction and prior activity. *Journal of Musculoskeletal Research.*
 1055 2018;21(2):1850010 (1850013 pages).
- 1056 94. Rosier P, Schaefer W, Lose G, et al. International Continence Society Good Urodynamic
 1057 Practices and Terms 2016: Urodynamics, uroflowmetry, cystometry, and pressure-flow study.
 1058 *Neurourol Urodyn.* 2017;36(5):1243-1260.

- 1059 95. Frawley HC, Galea MP, Phillips BA, Sherburn M, Bo K. Reliability of pelvic floor muscle
1060 strength assessment using different test positions and tools. *Neurourol Urodyn.*
1061 2006;25(3):236-242.
- 1062 96. Hundley AF, Wu JM, Visco AG. A comparison of perineometer to brink score for assessment
1063 of pelvic floor muscle strength. *Am J Obstet Gynecol.* 2005;192(5):1583-1591.
- 1064 97. Bo K, Kvarstein B, Hagen R, Larsen S. Pelvic floor muscle exercises for the treatment of
1065 female stress urinary incontinence : II. Validity of vaginal pressure measurements of pelvic
1066 floor muscle strenght and the necessity of supplementary methods for control of correct
1067 contraction. *Neurourol Urodyn.* 1990;9:479-487.
- 1068 98. Bump RC, Mattiasson A, Bo K, et al. The standardization of terminology of female pelvic
1069 organ prolapse and pelvic floor dysfunction. *Am J Obstet Gynecol.* 1996;175(1):10-17.
- 1070 99. Bo K, Constantinou C. Reflex contraction of pelvic floor muscles during cough cannot be
1071 measured with vaginal pressure devices. *Neurourol Urodyn.* 2011;30(7):1404.
- 1072 100. Deffieux X, Raibaut P, Rene-Corail P, et al. External anal sphincter contraction during cough:
1073 not a simple spinal reflex. *Neurourol Urodyn.* 2006;25(7):782-787.
- 1074 101. Rahmani N, Mohseni-Bandpei MA. Application of perineometer in the assessment of pelvic
1075 floor muscle strength and endurance: a reliability study. *J Bodyw Mov Ther.* 2011;15(2):209-
1076 214.
- 1077 102. Sigurdardottir T, Steingrimsdottir T, Arnason A, Bo K. Test-retest intra-rater reliability of
1078 vaginal measurement of pelvic floor muscle strength using Myomed 932. *Acta Obstet Gynecol*
1079 *Scand.* 2009;88(8):939-943.
- 1080 103. Ferreira CH, Barbosa PB, de Oliveira Souza F, Antonio FI, Franco MM, Bo K. Inter-rater
1081 reliability study of the modified Oxford Grading Scale and the Peritron manometer.
1082 *Physiotherapy.* 2011;97(2):132-138.
- 1083 104. Quartly E, Hallam T, Kilbreath S, Refshauge K. Strength and endurance of the pelvic floor
1084 muscles in continent women: an observational study. *Physiotherapy.* 2010;96(4):311-316.
- 1085 105. Batista EM, Conde DM, Do Amaral WN, Martinez EZ. Comparison of pelvic floor muscle
1086 strength between women undergoing vaginal delivery, cesarean section, and nulliparae using a
1087 perineometer and digital palpation. *Gynecol Endocrinol.* 2011;27(11):910-914.
- 1088 106. Ribeiro Jdos S, Guirro EC, Franco Mde M, Duarte TB, Pomini JM, Ferreira CH. Inter-rater
1089 reliability study of the Peritron perineometer in pregnant women. *Physiother Theory Pract.*
1090 2016;32(3):209-217.
- 1091 107. Braekken IH, Majida M, Engh ME, Bo K. Are pelvic floor muscle thickness and size of levator
1092 hiatus associated with pelvic floor muscle strength, endurance and vaginal resting pressure in
1093 women with pelvic organ prolapse stages I-III? A cross sectional 3D ultrasound study.
1094 *Neurourol Urodyn.* 2014;33(1):115-120.
- 1095 108. Friedman S, Blomquist JL, Nugent JM, McDermott KC, Munoz A, Handa VL. Pelvic muscle
1096 strength after childbirth. *Obstet Gynecol.* 2012;120(5):1021-1028.
- 1097 109. Vollebregt PF, Rasijeff AMP, Pares D, et al. Functional anal canal length measurement using
1098 high-resolution anorectal manometry to investigate anal sphincter dysfunction in patients with
1099 fecal incontinence or constipation. *Neurogastroenterol Motil.* 2019;31(3).
- 1100 110. Carrington EV, Scott SM, Bharucha A, et al. Expert consensus document: Advances in the
1101 evaluation of anorectal function. *Nat Rev Gastroenterol Hepatol.* 2018;15(5):309-323.
- 1102 111. Broens PMA, Penninckx FM, Ochoa JB. Fecal Continence Revisited: The Anal External
1103 Sphincter Continence Reflex. *Dis Colon Rectum.* 2013;56(11):1273-1281.
- 1104 112. Zbar AP, Aslam M, Gold DM, Gatzen C, Gosling A, Kmiot WA. Parameters of the rectoanal
1105 inhibitory reflex in patients with idiopathic fecal incontinence and chronic constipation. *Dis*
1106 *Colon Rectum.* 1998;41(2):200-208.
- 1107 113. JElectKin_Recommendations. Standards for Reporting EMG Data. *J Electromyogr Kinesiol.*
1108 2017;34(Supplement C):I-II.

- 1109 114. Clancy EA, Negro F, Farina D. Single-channel techniques for information extraction from the
1110 surface EMG signal. In: Merletti R, Farina D, eds. *Surface Electromyography : Physiology,*
1111 *Engineering and Applications.* Hoboken, New Jersey: John Wiley & Sons, Incorporated;
1112 2016:731.
- 1113 115. Vigotsky AD, Halperin I, Lehman GJ, Trajano GS, Vieira TM. Interpreting Signal Amplitudes
1114 in Surface Electromyography Studies in Sport and Rehabilitation Sciences. *Front Physiol.*
1115 2017;8:985.
- 1116 116. Enoka RM, Duchateau J. Inappropriate interpretation of surface EMG signals and muscle fiber
1117 characteristics impedes understanding of the control of neuromuscular function. *J Appl Physiol*
1118 *(1985).* 2015;119(12):1516-1518.
- 1119 117. Disselhorst-Klug C, Schmitz-Rode T, Rau G. Surface electromyography and muscle force:
1120 limits in sEMG-force relationship and new approaches for applications. *Clin Biomech (Bristol,*
1121 *Avon).* 2009;24(3):225-235.
- 1122 118. Farina D, Stegeman DF, Merletti R. Biophysics of the generation of EMG signals. In: Merletti
1123 R, Farina D, eds. *Surface Electromyography : Physiology, Engineering and Applications.*
1124 Hoboken, New Jersey: John Wiley & Sons, Incorporated; 2016:731.
- 1125 119. Merletti R, Farina D. Analysis of intramuscular electromyogram signals. *Philos Trans A Math*
1126 *Phys Eng Sci.* 2009;367(1887):357-368.
- 1127 120. Podnar S, Vodusek DB. Protocol for clinical neurophysiologic examination of the pelvic floor.
1128 *Neurourol Urodyn.* 2001;20(6):669-682.
- 1129 121. Vodusek DB. Electromyography. In: Bo K, Berghmans B, Morkved S, Van Kampen M, eds.
1130 *Evidence-based physical therapy for the pelvic floor.* Second edition ed.: Churchill
1131 Livingstone; 2015.
- 1132 122. Bianchi F, Squintani GM, Osio M, et al. Neurophysiology of the pelvic floor in clinical
1133 practice: a systematic literature review. *Funct Neurol.* 2017;22(4):173-193.
- 1134 123. Basmajian JV. New views on muscular tone and relaxation. *Can Med Assoc.* 1957;77:203-205.
- 1135 124. Clemmesen S. Some studies on muscle tone. *Proc R Soc Med.* 1951;44(8):637-646.
- 1136 125. Smith MD, Coppieters MW, Hodges PW. Postural response of the pelvic floor and abdominal
1137 muscles in women with and without incontinence. *Neurourol Urodyn.* 2007;26(3):377-385.
- 1138 126. Moser H, Leitner M, Baeyens JP, Radlinger L. Pelvic floor muscle activity during impact
1139 activities in continent and incontinent women: a systematic review. *Int Urogynecol J.*
1140 2018;29(2):179-196.
- 1141 127. Brueckner D, Kiss R, Muehlbauer T. Associations Between Practice-Related Changes in Motor
1142 Performance and Muscle Activity in Healthy Individuals: A Systematic Review. *Sports Med*
1143 *Open.* 2018;4(1):9.
- 1144 128. Dewaele P, Deffieux X, Villot A, Billecocq S, Amarenco G, Thubert T. Effect of body position
1145 on reflex and voluntary pelvic floor muscle contraction during a distraction task. *Neurourol*
1146 *Urodyn.* 2018.
- 1147 129. McCrary JM, Ackermann BJ, Halaki M. EMG amplitude, fatigue threshold, and time to task
1148 failure: A meta-analysis. *J Sci Med Sport.* 2017.
- 1149 130. Mohseni Bandpei MA, Rahmani N, Majdoleslam B, Abdollahi I, Ali SS, Ahmad A. Reliability
1150 of surface electromyography in the assessment of paraspinal muscle fatigue: an updated
1151 systematic review. *J Manipulative Physiol Ther.* 2014;37(7):510-521.
- 1152 131. Glazer HI, Romanzi L, Polaneczky M. Pelvic floor muscle surface electromyography.
1153 Reliability and clinical predictive validity. *J Reprod Med.* 1999;44(9):779-782.
- 1154 132. Dietz HP. Quantification of major morphological abnormalities of the levator ani. *Ultrasound*
1155 *Obstet Gynecol.* 2007;29(3):329-334.
- 1156 133. Dietz HP, Shek KL. Tomographic ultrasound imaging of the pelvic floor: which levels matter
1157 most? *Ultrasound Obstet Gynecol.* 2009;33(6):698-703.

- 1158 134. Sherburn M, Murphy CA, Carroll S, Allen TJ, Galea MP. Investigation of transabdominal real-
1159 time ultrasound to visualise the muscles of the pelvic floor. *Aust J Physiother.* 2005;51(3):167-
1160 170.
- 1161 135. Thompson JA, O'Sullivan PB, Briffa K, Neumann P, Court S. Assessment of pelvic floor
1162 movement using transabdominal and transperineal ultrasound. *Int Urogynecol J.*
1163 2005;16(4):285-292.
- 1164 136. Bo K, Sherburn M, Allen T. Transabdominal ultrasound measurement of pelvic floor muscle
1165 activity when activated directly or via a transversus abdominis muscle contraction. *Neurourol*
1166 *Urodyn.* 2003;22(6):582-588.
- 1167 137. Dietz H, Hoyte L, Steensma A. Atlas of pelvic floor ultrasound. *Springer-Verlag London*
1168 *Limited.* 2008.
- 1169 138. Dietz HP. Pelvic Floor Ultrasound: A Review. *Clin Obstet Gynecol.* 2017;60(1):58-81.
- 1170 139. Lone F, Sultan AH, Stankiewicz A, Thakar R. Interobserver agreement of multicompartiment
1171 ultrasound in the assessment of pelvic floor anatomy. *Br J Radiol.* 2016;89(1059):20150704.
- 1172 140. Schaer G. The clinical value of sonographic imaging of the urethrovesical anatomy. *Scand J*
1173 *Urol Nephrol Suppl.* 2001(207):80-86; discussion 106-125.
- 1174 141. Dietz HP, Wilson PD, Clarke B. The use of perineal ultrasound to quantify levator activity and
1175 teach pelvic floor muscle exercises. *Int Urogynecol J.* 2001;12(3):166-168; discussion 168-
1176 169.
- 1177 142. Reddy AP, DeLancey JO, Zwica LM, Ashton-Miller JA. On-screen vector-based ultrasound
1178 assessment of vesical neck movement. *Am J Obstet Gynecol.* 2001;185(1):65-70.
- 1179 143. Shek KL, Dietz HP. The urethral motion profile: a novel method to evaluate urethral support
1180 and mobility. *Aust N Z J Obstet Gynaecol.* 2008;48(3):337-342.
- 1181 144. Haylen BT, de Ridder D, Freeman RM, et al. An International Urogynecological Association
1182 (IUGA)/International Continence Society (ICS) Joint Report on the Terminology for Female
1183 Pelvic Floor Dysfunction. *Neurourol Urodyn.* 2010;29(1):4-20.
- 1184 145. Majida M, Braekken IH, Umek W, Bo K, Saltyte Benth J, Ellstrom Engh M. Interobserver
1185 repeatability of three- and four-dimensional transperineal ultrasound assessment of pelvic floor
1186 muscle anatomy and function. *Ultrasound Obstet Gynecol.* 2009;33(5):567-573.
- 1187 146. Thibault-Gagnon S, Auchincloss C, Graham R, McLean L. The temporal relationship between
1188 activity of the pelvic floor muscles and motion of selected urogenital landmarks in healthy
1189 nulliparous women. *J Electromyogr Kinesiol.* 2018;38:126-135.
- 1190 147. Morin M, Bergeron S, Khalife S, Mayrand MH, Binik YM. Morphometry of the pelvic floor
1191 muscles in women with and without provoked vestibulodynia using 4D ultrasound. *J Sex Med.*
1192 2014;11(3):776-785.
- 1193 148. Braekken IH, Majida M, Ellstrom-Engh M, Dietz HP, Umek W, Bo K. Test-retest and intra-
1194 observer repeatability of two-, three- and four-dimensional perineal ultrasound of pelvic floor
1195 muscle anatomy and function. *Int Urogynecol J.* 2008;19(2):227-235.
- 1196 149. Dietz HP, Jarvis SK, Vancaillie TG. The Assessment of Levator Muscle Strength: A Validation
1197 of Three Ultrasound Techniques. *Int Urogynecol J.* 2002;13(3):156-159.
- 1198 150. Braekken IH, Majida M, Engh ME, Bo K. Test-retest reliability of pelvic floor muscle
1199 contraction measured by 4D ultrasound. *Neurourol Urodyn.* 2009;28(1):68-73.
- 1200 151. Costantini S, Esposito F, Nadalini C, et al. Ultrasound imaging of the female perineum: the
1201 effect of vaginal delivery on pelvic floor dynamics. *Ultrasound Obstet Gynecol.*
1202 2006;27(2):183-187.
- 1203 152. Beer-Gabel M, Teshler M, Barzilai N, et al. Dynamic transperineal ultrasound in the diagnosis
1204 of pelvic floor disorders: pilot study. *Dis Colon Rectum.* 2002;45(2):239-245; discussion 245-
1205 238.

- 1206 153. Stafford RE, Ashton-Miller JA, Constantinou CE, Hodges PW. Novel Insight into the
1207 Dynamics of Male Pelvic Floor Contractions Through Transperineal Ultrasound Imaging. *J*
1208 *Urol.* 2012;188(4):1224-1230.
- 1209 154. Stafford RE, Coughlin G, Hodges PW. Comparison of dynamic features of pelvic floor muscle
1210 contraction between men with and without incontinence after prostatectomy and men with no
1211 history of prostate cancer. *Neurourol Urodyn.* 2020;39(1):170-180.
- 1212 155. Aljuraifani R, Stafford RE, Hug F, Hodges PW. Female striated urogenital sphincter
1213 contraction measured by shear wave elastography during pelvic floor muscle activation: Proof
1214 of concept and validation. *Neurourol Urodyn.* 2018;37(1):206-212.
- 1215 156. Dietz HP, Shek C, Clarke B. Biometry of the pubovisceral muscle and levator hiatus by three-
1216 dimensional pelvic floor ultrasound. *Ultrasound Obstet Gynecol.* 2005;25(6):580-585.
- 1217 157. Dietz HP, Shek C, De Leon J, Steensma AB. Ballooning of the levator hiatus. *Ultrasound*
1218 *Obstet Gynecol.* 2008;31(6):676-680.
- 1219 158. Braekken IH, Majida M, Engh ME, Bo K. Morphological changes after pelvic floor muscle
1220 training measured by 3-dimensional ultrasonography: a randomized controlled trial. *Obstet*
1221 *Gynecol.* 2010;115(2 Pt 1):317-324.
- 1222 159. Dietz HP, Abbu A, Shek KL. The levator-urethra gap measurement: a more objective means
1223 of determining levator avulsion? *Ultrasound Obstet Gynecol.* 2008;32(7):941-945.
- 1224 160. Digesu GA, Robinson D, Cardozo L, Khullar V. Three-dimensional ultrasound of the urethral
1225 sphincter predicts continence surgery outcome. *Neurourol Urodyn.* 2009;28(1):90-94.
- 1226 161. Ismail S, Morin M, Tu LM. Assessment of the effects of autologous muscle derived cell
1227 injections on urethral sphincter morphometry using 3D/4D ultrasound. *World J Urol.*
1228 2020;(accepted for publication, 2020 Jan 14).
- 1229 162. Robinson D, Toozs-Hobson P, Cardozo L, Digesu A. Correlating structure and function: three-
1230 dimensional ultrasound of the urethral sphincter. *Ultrasound Obstet Gynecol.* 2004;23(3):272-
1231 276.
- 1232 163. Athanasiou S, Khullar V, Boos K, Salvatore S, Cardozo L. Imaging the urethral sphincter with
1233 three-dimensional ultrasound. *Obstet Gynecol.* 1999;94(2):295-301.
- 1234 164. Madill SJ, Pontbriand-Drolet S, Tang A, Dumoulin C. Changes in urethral sphincter size
1235 following rehabilitation in older women with stress urinary incontinence. *Int Urogynecol J.*
1236 2015;26(2):277-283.
- 1237 165. Guzman Rojas RA, Kamisan Atan I, Shek KL, Dietz HP. Anal sphincter trauma and anal
1238 incontinence in urogynecological patients. *Ultrasound Obstet Gynecol.* 2015;46(3):363-366.
- 1239 166. Dietz HP. Exoanal Imaging of the Anal Sphincters. *J Ultrasound Med.* 2018;37(1):263-280.
- 1240 167. Rostaminia G, Peck J, Quiroz L, Shobeiri SA. Levator Plate Upward Lift on Dynamic
1241 Sonography and Levator Muscle Strength. *J Ultrasound Med.* 2015;34(10):1787-1792.
- 1242 168. Santoro GA, Shobeiri SA, Petros PP, Zapater P, Wiczorek AP. Perineal body anatomy seen
1243 by three-dimensional endovaginal ultrasound of asymptomatic nulliparae. *Colorectal Dis.*
1244 2016;18(4):400-409.
- 1245 169. Shobeiri SA, Rostaminia G, White D, Quiroz L. The determinants of minimal levator hiatus
1246 and their relationship to the puborectalis muscle and the levator plate. *BJOG.* 2013;120(2):205-
1247 211.
- 1248 170. Rostaminia G, Manonai J, Leclaire E, et al. Interrater reliability of assessing levator ani
1249 deficiency with 360° 3D endovaginal ultrasound. *Int Urogynecol J.* 2014;25(6):761-766.
- 1250 171. Rostaminia G, Peck JD, Quiroz LH, Shobeiri SA. Characteristics associated with pelvic organ
1251 prolapse in women with significant levator ani muscle deficiency. *Int Urogynecol J.*
1252 2016;27(2):261-267.
- 1253 172. Thakar R, Sultan AH. Anal endosonography and its role in assessing the incontinent patient.
1254 *Best Pract Res Clin Obstet Gynaecol.* 2004;18(1):157-173.

- 1255 173. Abdool Z, Sultan AH, Thakar R. Ultrasound imaging of the anal sphincter complex: a review.
1256 *Br J Radiol.* 2012;85(1015):865-875.
- 1257 174. Sigrist RMS, Liao J, Kaffas AE, Chammas MC, Willmann JK. Ultrasound Elastography:
1258 Review of Techniques and Clinical Applications. *Theranostics.* 2017;7(5):1303-1329.
- 1259 175. Stafford RE, Aljuraifani R, Hug F, Hodges PW. Application of shear-wave elastography to
1260 estimate the stiffness of the male striated urethral sphincter during voluntary contractions. *BJU*
1261 *Int.* 2017;119(4):619-625.
- 1262 176. Xie M, Feng Y, Zhang XY, Hua KQ, Ren YY, Wang WP. Evaluation of pelvic floor muscle
1263 by transperineal elastography in patients with deep infiltrating endometriosis: preliminary
1264 observation. *Journal of Medical Ultrasonics.* 2019;46(1):123-128.
- 1265 177. Xie M, Zhang XY, Liu J, Ding JX, Ren YY, Hua KQ. Evaluation of levator ani with no defect
1266 on elastography in women with POP. *Int J Clin Exp Med.* 2015;8(6):10204-10212.
- 1267 178. Gachon B, Nordez A, Pierre F, Fradet L, Fritel X, Desseauve D. In vivo assessment of the
1268 levator ani muscles using shear wave elastography: a feasibility study in women. *Int*
1269 *Urogynecol J.* 2019;30(7):1179-1186.
- 1270 179. Morin M, Salomoni S, Stafford R, Hall L, Hodges PW. Validation of shear-wave elastography
1271 for evaluating pelvic floor muscle stiffness. *Neurorol Urodyn.* 2019;38(S3):436-438.
- 1272 180. Paluch L, Nawrocka-Laskus E, Wieczorek J, Mruk B, Frel M, Walecki J. Use of Ultrasound
1273 Elastography in the Assessment of the Musculoskeletal System. *Polish Journal of Radiology.*
1274 2016;81:240-246.
- 1275 181. Taljanovic MS, Gimber LH, Becker GW, et al. Shear-Wave Elastography: Basic Physics and
1276 Musculoskeletal Applications. *Radiographics.* 2017;37(3):855-870.
- 1277 182. la Torre MF, Magarelli N, Cipriani A, et al. Applications of Ultrasound Elastography in
1278 Musculoskeletal Imaging: Technical Aspects and Review of the Literature. *Curr Med Imaging*
1279 *Rev.* 2017;13(3):251-259.
- 1280 183. Kreutzkamp JM, Schaefer SD, Amler S, Strube F, Kiesel L, Schmitz R. Strain elastography as
1281 a new method for assessing pelvic floor biomechanics. *Ultrasound Med Biol.* 2017;43(4):868-
1282 872.
- 1283 184. Merriam-Webster. Merriam-Webster Online Dictionary. In: [http://www.merriam-](http://www.merriam-webster.com/dictionary/)
1284 [webster.com/dictionary/](http://www.merriam-webster.com/dictionary/)
- 1285 185. Bo K, Frawley HC, Haylen BT, et al. An International Urogynecological Association
1286 (IUGA)/International Continence Society (ICS) joint report on the terminology for the
1287 conservative and nonpharmacological management of female pelvic floor dysfunction. *Int*
1288 *Urogynecol J.* 2017;28(2):191-213.
- 1289 186. Cyr MP, Bourbonnais D, Pinard A, Dubois O, Morin M. Reliability and Convergent Validity
1290 of the Algometer for Vestibular Pain Assessment in Women with Provoked Vestibulodynia.
1291 *Pain Med.* 2016;17(7):1220-1228.
- 1292 187. Pukall CF, Young RA, Roberts MJ, Sutton KS, Smith KB. The vulvalgesiometer as a device
1293 to measure genital pressure-pain threshold. *Physiol Meas.* 2007;28(12):1543-1550.
- 1294 188. Zolnoun D, Bair E, Essick G, Gracely R, Goyal V, Maixner W. Reliability and Reproducibility
1295 of Novel Methodology for Assessment of Pressure Pain Sensitivity in Pelvis. *J Pain.*
1296 2012;13(9):910-920.
- 1297 189. Loving S, Thomsen T, Jaszczak P, Nordling J. Pelvic floor muscle dysfunctions are prevalent
1298 in female chronic pelvic pain: A cross-sectional population-based study. *Eur J Pain.*
1299 2014;18(9):1259-1270.
- 1300 190. Tu FF, Fitzgerald CM, Kuiken T, Farrell T, Norman Harden R. Vaginal pressure-pain
1301 thresholds: Initial validation and reliability assessment in healthy women. *Clin J Pain.*
1302 2008;24(1):45-50.
- 1303 191. Witzeman K, Nguyen RHN, Eanes A, As-Sanie S, Zolnoun D. Mucosal versus muscle pain
1304 sensitivity in provoked vestibulodynia. *J Pain Res.* 2015;8:549-555.

- 1305 192. Meister MR, Sutcliffe S, Ghetti C, et al. Development of a standardized, reproducible screening
1306 examination for assessment of pelvic floor myofascial pain. *Am J Obstet Gynecol.* 2019;220(3).
1307 193. IASP. IASP Terminology, updated from Part III. In: December 14, 2017 ed. [https://www.iasp-](https://www.iasp-pain.org/Education/Content.aspx?ItemNumber=1698#Painthreshold2017)
1308 [pain.org/Education/Content.aspx?ItemNumber=1698#Painthreshold2017](https://www.iasp-pain.org/Education/Content.aspx?ItemNumber=1698#Painthreshold2017). Accessed
1309 24Feb2020.
- 1310 194. Ohrbach R, Gale EN. Pressure pain thresholds in normal muscles - reliability, measurement
1311 effects, and topographic differences. *Pain.* 1989;37(3):257-263.
- 1312 195. Sanses TVD, Chelimsky G, McCabe NP, et al. The Pelvis and Beyond: Musculoskeletal Tender
1313 Points in Women With Chronic Pelvic Pain. *Clin J Pain.* 2016;32(8):659-665.
- 1314 196. Park G, Kim CW, Park SB, Kim MJ, Jang SH. Reliability and Usefulness of the Pressure Pain
1315 Threshold Measurement in Patients with Myofascial Pain. *Annals of Rehabilitation Medicine-*
1316 *Arm.* 2011;35(3):412-417.
- 1317 197. Rezaei T, Hirschberg AL, Carlstrom K, Ernberg M. The Influence of Menstrual Phases on Pain
1318 Modulation in Healthy Women. *J Pain.* 2012;13(7):646-655.
- 1319 198. Chesterton LS, Barlasb P, Foster NE, Baxter GD, Wright CC. Gender differences in pressure
1320 pain threshold in healthy humans. *Pain.* 2003;101(3):259-266.
- 1321 199. Dictionary M. The Free Dictionary. <http://medical-dictionary.thefreedictionary.com/>
1322 200. ICD. ICD Codes. https://www.cdc.gov/nchs/data/icd/10cmguidelines-FY2020_final.pdf.
- 1323 201. Sinaki M, Merritt JL, Stillwell GK. Tension myalgia of the pelvic floor. *Mayo Clin Proc.*
1324 1977;52(11):717-722.
- 1325 202. Chen Q, Bensamoun S, Basford JR, Thompson JM, An KN. Identification and quantification
1326 of myofascial taut bands with magnetic resonance elastography. *Arch Phys Med Rehabil.*
1327 2007;88(12):1658-1661.
- 1328 203. Sikdar S, Shah JP, Gebreab T, et al. Novel Applications of Ultrasound Technology to Visualize
1329 and Characterize Myofascial Trigger Points and Surrounding Soft Tissue. *Arch Phys Med*
1330 *Rehabil.* 2009;90(11):1829-1838.
- 1331 204. Rao SSC, Patcharatrakul T. Diagnosis and Treatment of Dyssynergic Defecation. *J*
1332 *Neurogastroenterol Motil.* 2016;22(3):423-435.
- 1333 205. Rao SSC. Constipation: Evaluation and treatment of colonic and anorectal motility disorders.
1334 *Gastroenterol Clin North Am.* 2007;36(3):687-+.
- 1335 206. DSMMD. *Diagnostic and statistical manual of mental disorders: DSM-5.* 5th ed. ed.
1336 Arlington, VA: American Psychiatric Association; 2013.
- 1337 207. Parish SJ, Cottler-Casanova S, Clayton AH, McCabe MP, Coleman E, Reed GM. The
1338 Evolution of the Female Sexual Disorder/Dysfunction Definitions, Nomenclature, and
1339 Classifications: A Review of DSM, ICSM, ISSWSH, and ICD. *Sex Med Rev.* 2020.
- 1340 208. Kaur J, Singh P. Pudendal Nerve Entrapment Syndrome. In: Vol in StatPearls Publishing;
1341 2019: <https://www.ncbi.nlm.nih.gov/books/NBK544272/>.
- 1342 209. Labat JJ, Riant T, Robert R, Amarenco G, Lefaucheur JP, Rigaud J. Diagnostic criteria for
1343 pudendal neuralgia by pudendal nerve entrapment (Nantes criteria). *NeuroUrol Urodyn.*
1344 2008;27(4):306-310.
- 1345