

## EB VIRUS IN INTERSTITIAL CYSTITIS/BLADDER PAIN SYNDROME – AN IMMUNOCHEMICAL STUDY

### Hypothesis / aims of study

Pathogenesis of ulcer type interstitial cystitis/bladder pain syndrome (IC/BPS) might be different from the non-ulcer IC/BPS. Previous study revealed subepithelial lymphoplasmacytic infiltration with focal lymphocyte aggregation in the bladder of ulcer IC/BPS. However, the etiology is still unknown. The aim of current study is to investigate the role of EB virus in the pathogenesis of IC/BPS, including ulcer and non-ulcer type.

### Study design, materials and methods

A total of 33 patients with IC/BPS were enrolled. Thirteen of these patients were severe IC/BPS and were admitted to our ward for partial cystectomy with augmentation enterocystoplasty (10 ulcer type and 3 non-ulcer IC/BPS). The others 20 patients were mild IC/BPS and were admitted for cystoscopic hydrodistention with cold-cup bladder biopsy. The bladder specimens were obtained during the operation and sent to our pathology department for immunochemical staining for EB virus. Immunochemical staining cell markers CD3 for T lymphocyte and CD20 for B lymphocyte were also performed in the ulcer IC/BPS bladder. Blood samples for EB virus serological markers were obtained in the patients with positive immunochemical finding, including EB-VCA IgG, IgM, EBEA IgG and EBNA IgG. Twelve female patients who were admitted for anti-incontinence surgery were also enrolled and were considered as normal controls. Bladder mucosa biopsies were taken during the procedure, and the specimens were also sent to the pathology department for immunochemical staining for EB virus.

### Results

Among the severe 13 IC/BPS bladder specimens from partial cystectomy, immunochemical staining revealed EB virus positive in 7 patients (7/13=53.8%) (Figure 1). Five of the 7 patients were ulcer type IC/BPS, and the others 2 patients were non-ulcer IC/BPS. The EB virus positive rate was 5/10=50% in the ulcer IC/BPS bladder specimens, and was 2/3=66% in the non-ulcer IC/BPS bladder. None of the mild 20 IC/BPS or 12 normal control bladder specimen was positive for EB virus. The immunochemical staining also showed CD3 positive in the EB virus positive cells. The serological tests for EV virus revealed EB-VCA IgG and EBNA positive in all patients. The serum EBNA IgG was positive in only one patient, and EB-VCA IgM was all negative. The clinical symptoms severity was not significantly different between IC/BPS patients with or without EB virus positive.

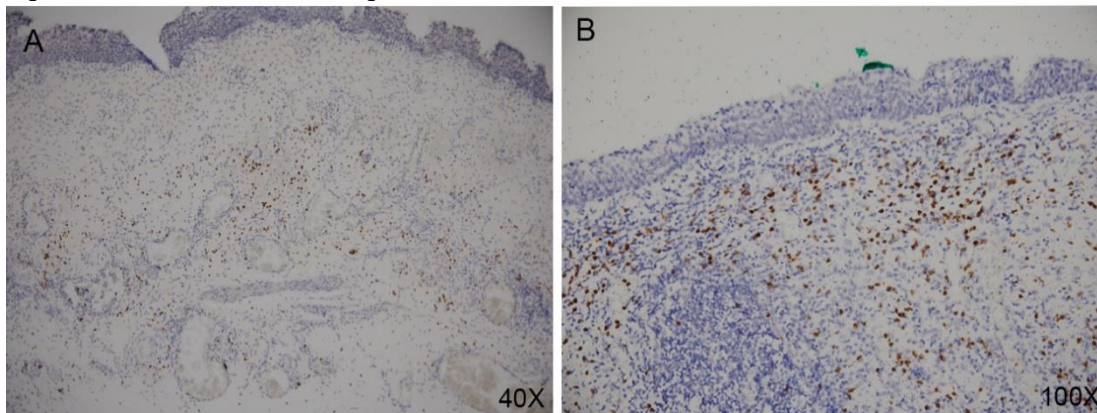
### Interpretation of results

Current study revealed about 50% EB virus positive in patients with severe IC/BPS who underwent enterocystoplasty. EB virus infected T cells were also found in the immunochemical staining. The serological markers also revealed a chronic infection in these patients. IC/BPS is a heterogeneous syndrome, and EB virus infection may involve the pathogenesis in some IC/BPS patients with severe clinical symptoms. In the patients with mild IC/BPS, immunochemical staining showed EB virus negative in all bladder biopsies. It suggested the pathogenesis between mild and severe IC/BPS might be different.

### Concluding message

EB virus infection in bladder T cells was found in patients with severe IC/BPS. EB virus infection and following immune response may involve the pathogenesis in IC/BPS patients with severe symptoms.

Figure 1. Immunochemical staining for EB virus in IC/BPS bladder.



The immunochemical staining revealed EB virus positive cell in (A) non-ulcer IC/BPS bladder (40X), and ulcer IC/BPS bladder (100X).

### Disclosures

**Funding:** none **Clinical Trial:** No **Subjects:** HUMAN **Ethics Committee:** Research Ethics Committee, Hualien Tzu Chi Hospital, Buddhist Tzu Chi Medical Foundation **Helsinki:** Yes **Informed Consent:** Yes