

ENLARGEMENT OF THE LEVATOR HIATUS IN FEMALE PELVIC ORGAN PROLAPSE: CAUSE OR EFFECT?

Hypothesis / aims of study

Female pelvic organ prolapse (FPOP) is likely due to a combination of factors including genetic predisposition and environmental factors, with pregnancy and childbirth likely to be most important amongst the latter. FPOP is a common problem: in Australia, almost 1/5 of all women can expect to require prolapse surgery at least once in their lifetime(1).

The levator hiatus defines the 'hernial portal' through which female pelvic organ prolapse develops. The larger the hiatus, the greater the likelihood of FPOP(2). It is however not clear whether excessive distensibility of the levator hiatus ('ballooning') is a cause or just the effect of FPOP. We undertook an observational study to determine whether patients after prolapse repair show changed levator biometry. If increased hiatal dimensions were an effect of prolapse, then successful prolapse correction should normalize hiatal dimensions.

Study design, materials and methods

This is a retrospective analysis of clinical and translabial ultrasound volume data of women who underwent prolapse surgery between March 05 and April 09. Clinical examination for prolapse grading was performed using the Pelvic Organ Prolapse Quantification System of the International Continence Society (ICS POP-Q). Ultrasound volume data were acquired using a Voluson 730 expert system with RAB 8-4 Mhz transducer with the patient supine and after voiding (3). Ultrasound postprocessing analysis was performed by the first author using the software 4D View versions 5.0- 7.0. We measured hiatal area as previously described, using the axial plane of minimal hiatal dimensions (2), in both pre- and postoperative volume datasets, the latter obtained in the context of our surgical audit program. In order to compare pre- and postoperative volume datasets that would maximise any effect of surgical cure, we analysed ultrasound volume data acquired at postoperative follow-up appointments between 3 and 12 months after the index surgery.

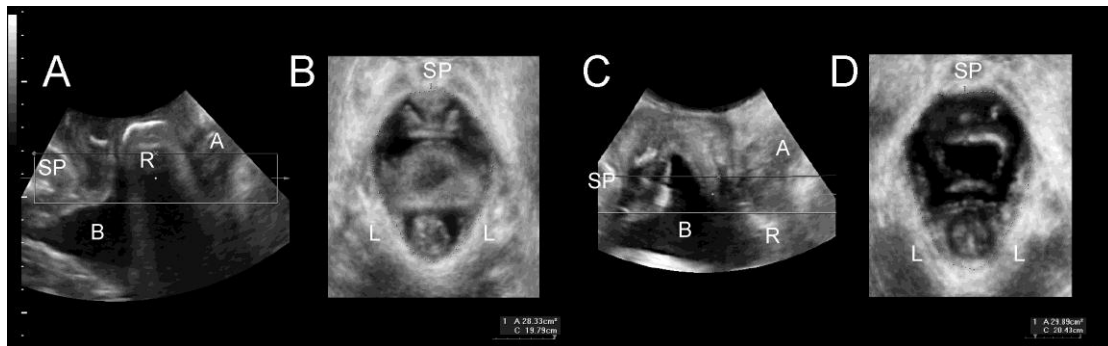


Figure 1: Determination of hiatal dimensions by axial plane translabial ultrasound on Valsalva. A and C show midsagittal planes, B and D axial planes. A and B show the preoperative status, C and D the same planes 5 months after a successful defect-specific rectocele repair. Hiatal area is virtually unchanged (28.3 vs. 29.9 cm²). SP= symphysis pubis, B= bladder, R= rectocele/ rectal ampulla, A= anal canal, L= levator ani.

The study was conducted in the context of a parent project that had been approved by the local institutional Human Research Ethics Committee. Statistical analysis was undertaken using the software Minitab v13 for PC (Mintab Inc., State College, PA, USA) and SAS v9.2 (SAS Institute Inc., Cary, NC, USA.). Levator avulsion, type of surgery, mesh use, symptoms of recurrent prolapse and length of FU were tested in logistic regression as potential confounders.

Results

94 women were identified as having undergone prolapse surgery during the inclusion period, and as having documented preoperative volume datasets that could be evaluated. Of those 94 patients, 83 had been seen between 3 and 12 months after their surgery, but in two cases the Valsalva volume dataset was missing, leaving 81. All subsequent analysis refers to those 81 patients. Mean age was 60.2 (SD± 11.1). All had given birth vaginally. Fifty-four had a previous hysterectomy, prolapse or incontinence surgery. 72 had symptoms of prolapse; nine women with rectocele were operated on because of symptoms of obstructed defecation. All had a symptomatic prolapse which was a cystocele in 45, apical prolapse in 24, an enterocele in 19 and a rectocele in 58 cases. The following surgical procedures were performed: Transobturator sling (n=46), TVT (n=1), Anterior colporrhaphy (n=11), Anterior colporrhaphy with transobturator mesh (n=40), sacrospinous colpoxy (n=24), vaginal hysterectomy (n=8), posterior colporrhaphy (n=41), posterior vaginal mesh (n=8).

Median follow-up length was 5.6 months (IQR 4.3 to 6.2 months). Most were satisfied with the outcome (n=72, 89%). Twenty women (25%) complained of recurrent prolapse symptoms (a vaginal lump or dragging sensation). A prolapse stage 2+ in any compartment, whether operated on or not, was found in 27 (33%). In 2 cases ultrasound volume datasets at rest and in 8 cases volumes on PFMC were unavailable, leaving 79 for analysis of area at rest, and 73 for area on PFMC. The mean pre-operative hiatal area on valsalva was 31.9 (range 13.5-58.1, SD 10.0) cm². Mean post-operative hiatal area on valsalva was 28.9 (range 13.9-47.4; SD 7.3) cm² (see Table). Fifty-four (67%) still showed abnormal hiatal distensibility (ballooning), i.e., a hiatal area of

over 25 cm², compared to 60 (74%) pre-operatively. Data were normally distributed on testing with the Kolmogorov- Smirnov method.

	Pre-operative area (cm ²)	Post-operative area (cm ²)	P = (paired t-test)
Area at rest (n=79)	19.7 ± 5.1	18.8 ± 4.4	0.089
Area on valsalva (n=81)	31.9 ± 10.0	28.9 ± 7.3	0.001
Area on PFMC (n=73)	16.1 ± 4.3	15.7 ± 4.2	0.284

Table 1: Changes in hiatal dimensions between preoperative and short- term (3-12 months) postoperative findings.

In order to test for potential confounders, we performed logistic regression testing avulsion, type of surgery, mesh use, symptoms of recurrent prolapse, recurrent prolapse on examination and length of follow-up in the model. None was found to be significant.

Interpretation of results

In this study we found a small but significant reduction in hiatal area on Valsalva 3-12 months after prolapse surgery, of about 10% compared to preoperative values. Most patients continued to show abnormal distensibility (ballooning) postoperatively, regardless of symptoms or signs of prolapse. No significant change in hiatal area at rest or on PFMC were noted. Avulsion, type of surgery, mesh use, symptoms/ signs of recurrent prolapse and length of follow-up were not found to be significant confounders. These findings suggest that hiatal dimensions largely reflect the inherent biomechanical properties of the pelvic floor. Passive distension due to pelvic organ prolapse does not seem to play a major role.

Concluding message

Excessive distensibility of the levator hiatus is more likely to be cause rather than effect of female pelvic organ prolapse. It may in fact be an important aetiological factor. This implies that any procedure that reduces the size of the levator hiatus could be expected to potentially influence recurrence rates after reconstructive surgery.

<i>Specify source of funding or grant</i>	Nil
<i>Is this a clinical trial?</i>	No
<i>What were the subjects in the study?</i>	HUMAN
<i>Was this study approved by an ethics committee?</i>	Yes
<i>Specify Name of Ethics Committee</i>	SWAHS HREC (Nepean Campus)
<i>Was the Declaration of Helsinki followed?</i>	Yes
<i>Was informed consent obtained from the patients?</i>	No